

Available online on 15.08.2019 at <http://jddtonline.info>

Journal of Drug Delivery and Therapeutics

Open Access to Pharmaceutical and Medical Research

© 2011-18, publisher and licensee JDDT, This is an Open Access article which permits unrestricted non-commercial use, provided the original work is properly cited

Open  Access

Research Article

ANTI-DIABETIC EFFECT OF ETHANOL EXTRACT OF *Costus spicatus* JACQ. IN RHIZOME EXTRACT IN STREPTOZOTOCIN-INDUCED DIABETIC RATS – HISTOLOGICAL STUDY

Azhagu Madhavan S, Senthilkumar S, Andrews S, Ganesan S*

PG & Research Department of Zoology & Biotechnology, A.V.V.M. Sri Pushpam College (Autonomous) Poondi, Thanjavur – 613503, India.

ABSTRACT

Objective: The rats were randomly divided into 5 groups and each group consisted of 6 rats and the duration of treatment was 45 days. Body weight, fasting plasma glucose levels, SGOT, SGPT and ALP levels were measured.

Methods: Albino Wistar male rats; 10- weeks old with a bodyweight ranged between 180-250 g were used. Anti-diabetic effect of plant *Costus spicatus*. In rhizome extract of ethanol extract.

Result: The present study clearly indicates in the form of administration of *C. spicatus* rhizome extract towards glucose fed mice normalizes blood glucose level. Recent studies have revealed induced diabetic rats caused anti-diabetic effects. Histopathological studies of Pancreasin diabetic and treated groups are determined to show the protective action of the ECS. The administration of STZ resulted in a significant increase in plasma glucose level, SGOT, SGPT and ALP along with a reduction in body weight.

Conclusion: All these effects were observed on 45th day. ECS and Glibenclamide of STZ induced diabetic animals restored the normal plasma glucose levels and SGOT, SGPT and ALP levels without damaging the pancreas.

Keywords: Anti-hypolipidemic, diabetes mellitus, peripheral insulin resistance, pancreatic, STZ.

Article Info: Received 08 June 2019; Review Completed 28 July 2019; Accepted 06 Aug 2019; Available online 15 August 2019



Cite this article as:

AzhaguMadhavan S, Senthilkumar S, Andrews S, Ganesan S, ANTI-DIABETIC EFFECT OF ETHANOL EXTRACT OF *Costus spicatus* JACQ. IN RHIZOME EXTRACT IN STREPTOZOTOCIN-INDUCED DIABETIC RATS –HISTOLOGICAL STUDY, Journal of Drug Delivery and Therapeutics. 2019; 9(4-s):483-487 <http://dx.doi.org/10.22270/jddt.v9i4-s.3359>

*Address for Correspondence:

Dr GanesanSivamani, Assistant Professor (SG), PG & Research Department of Zoology and Biotechnology, A.V.V.M.Sri Pushpam College (Autonomous), Poondi – 613 503, Thanjavur Dt., Tamilnadu, India.

INTRODUCTION

Diabetes mellitus (DM) is one of the most important and largest epidemics public health challenges of the twenty-first century worldwide. DM, more simply called diabetes, is a chronic condition that occurs when there are raised levels of glucose in the blood because the body cannot produce any or enough of the hormone insulin or use insulin effectively. It is a metabolic disorder of multiple etiologies distinguished by a failure of glucose homeostasis with disturbances of carbohydrate, fat and protein metabolism as a result of defects in insulin secretion and/or insulin action ¹. The family of steroid hormone receptors, a major group of the nuclear receptor superfamily, includes proteins that bind hormones, hormone response elements and a variable number of coactivators or corepressors with a relatively high degree of specificity. As regulatory components of endocrine activities, steroid receptors are essential for maintaining biological function in eukaryotic organisms, including fetal development, postnatal growth, and normal physiological function. ²⁻³. Non-Insulin-Dependent Diabetes Mellitus (NIDDM), otherwise known as type 2 diabetes (T2D), is a

metabolic disorder characterized by insulin resistance, hyperglycemia and hyperinsulinemia, leading to chronic complications such as neuropathy, nephropathy, retinopathy and premature atherosclerosis ⁴⁻⁵. Long-standing T2DM can affect the vascular system leading to microvascular complications. The pathologic landmark of T2DM is microvascular complications, including nephropathy, retinopathy, neuropathy and microangiopathic cardiovascular disease (CVD). Interestingly, several studies report that tight glycemic control doesn't lower the incidence and progression of microvascular complications. Thus, presence of long-standing hyperglycemia doesn't explain microvascular complications in T2DM, and other factors would be contributing to the pathogenesis of such complications; identification of these factors should minimize the incidence of these complications and improve their management ⁶. Despite the opening of the hypoglycemic agent because of natural and synthetic sources. Many in the Indian medicinal plants have been useful to successfully manage diabetes mellitus. One of the great advantages of medicinal plants are readily available and contain very low side effects. The plant source of drugs and

many currently available drugs have been derived directly or indirectly from them. The ethnobotanical information reports about 800 plants species that may possess anti-diabetic plants potential⁷. The present study is conducted to investigate the antidiabetic compounds, the antidiabetic and hypolipidemic effect of *C. spicatus* ethanol rhizome extract in (STZ)-induced diabetic male albino rats.

MATERIALS AND METHODS

Animal

Albino Wistar male rats; 10- weeks old with a bodyweight ranged between 180-250 g were used. Animals were housed under standard conditions temperature (24±2°C) and relative humidity (30-70%) with a 12:12 (light: dark) conditions. The animals were fed with standard pellet diet. Animals were handled according to Good Laboratory Practice. Ethical clearance was obtained from the Committee for the Purpose of Control and Supervision of experiments on Animal (CPCSEA). Institutional Animal Ethics Committee (IAEC) RegNo:685/PO/Re/S/2002/ KMCRET/Ph.D/22/2018-19).

Collection, Identification and Authentication of plant species:

The plant, *Costus spicatus* were collected from the Saliyamangalam and Thanjavur district, Tamilnadu, India. It was taxonomically identified and authenticated by Rev Dr S. John Britto SJ, Director, The Rapinat Herbarium and Centre for Molecular Systematics, St. Joseph's College (Autonomous), Tiruchirappalli, Tamilnadu, India. The voucher specimens are deposited at the Rapinat herbarium and the voucher number is SAM 001.

Plant extraction

Rhizome was cut into small pieces and shade dried at room temperature. The dried rhizome was subjected to size reduction to a coarse powder by using the dry grinder and sieved. About 100 g was continuously extracted with ethanol (95%) using Soxhlet extractor up to 48 h. The extract was filtered through Whatman filter paper and concentrated using rotary evaporator at 40-60°C under reduced pressure to prepare the final crude extract (1g) weight.

Diabetes induction using Streptozotocin

Animals fasted overnight and diabetes was induced by single intraperitoneal injection of STZ (45mg/kg body weight) prepared in 0.1 M Citrate buffer at pH 4.5. To overcome drug-induced hypoglycemia, animals were allowed to drink a 5% glucose solution overnight. Citrate buffer in place of Streptozotocin was injected to control rats. After 72 hours of STZ injection, (taken as 0th day) fasting blood glucose levels of each animal was analyzed. Animals with fasting blood glucose levels > 200 mg/dl were considered diabetic and considered for the study.

Anti-diabetic treatment of animals

The rats were randomly divided into 5 groups and each group consisted of 6 rats and the duration of treatment was 45 days. Group I: Animals fed with distilled water (negative control). Group II: Diabetic animals fed with distilled water (positive control). Group III: Diabetic animals fed with Glibenclamide (5mg/kg/b.w./day). Group IV: Diabetic animals fed with ECS (300 mg/ kgb.w./day). Group V: Diabetic animals fed with ECS (500mg/kg/b.w./day). Before (0th), during (21st) and at the end of treatment (45th), body weight, fasting plasma glucose levels, SGOT, SGPT and ALP levels were measured. Plasma glucose levels were determined by Ortho Toluidine reagent method. SGOT, SGPT and ALP levels were measured from serum separated from the blood which was collected from the retro-orbital plexuses of the rats of all groups under light ether anaesthesia using a semiautomatic biochemical analyzer with commercially available biochemical kits.

Collection of tissue samples and histological analysis

After 45 days of treatment, animals were sacrificed following the guidelines of the animal ethical committee. The Pancreas tissues were excised and fixed in 10% neutral buffered formalin (NBF). Thus fixed Pancreas tissues were sectioned with Leica rotary microtome to produce serial sections of 5µm thickness. Pancreas sections were stained with Hematoxylin and Eosin (H&E) stains. The stained specimens were then analyzed and photomicrographed with APCAM-5 USB 2 digital camera attached to a computer monitor (ADELTAVISION OPTEC India microscope Ltd).

Statistical Analysis

One-way analysis of variance (ANOVA) was performed using the software "GraphpadInstat". Results were expressed as mean ± SEM. p<0.05 was considered as statistically significant.

RESULTS

Hyperglycaemia is an independent risk factor in the development of chronic diabetic complications. Their management of type 2 diabetes relies on the maintenance of blood glucose concentration in a normal or near-normal level. In Southeast Asia, it is used to treat boils, constipation, diarrhoea, dizziness, headache, ear, eye, and nose pain, and to stop vomiting. Japanese used the rhizome extract in control of syphilis⁸. The present study clearly indicates in the form of administration of *C. spicatus* rhizome extract towards glucose fed mice normalizes blood glucose level. Recent studies have revealed induced diabetic rats caused anti-diabetic effects. Histopathological studies of Pancreas in diabetic and treated groups are determined to show the protective action of the ECS. The administration of STZ resulted in a significant increase in plasma glucose level, SGOT, SGPT and ALP along with a reduction in body weight (Table 1, 2 & 3). After treatment of animals with 500 mg/kg/b.w of ECS, the plasma glucose levels significantly reduced and returned to normalcy (p<0.001), with a simultaneous increase in body weight (Table 1 & 2).

Table 1: Effect of ECS on body weight in normal & STZ induced diabetic rats

Groups	Change in Bodyweight (gm)		
	0 day	21 st day	45 st day
Group I	161±2.58	85.66±2.41	196.16±2.98
Group II	181.66±2.13**	161.83±1.47**	125.33±1.96**
Group III	171.33±2.15#	168.33±2.44**	188.16±1.97**
Group IV	175.16±1.60	185.50±2.14**	178.66±1.60**
Group V	191±2.78#	181.66±2.21**	184.50±1.45**

Results are expressed as mean ± SEM; n=6; **=p<0.001 and # =not significant

Table 2: Effect of ECS on plasma glucose values in normal & experimental rats

Groups	Change in Bodyweight (gm)		
	0 day	21 st day	45 day
Group I	97.16±2.12	96.33±1.76	95.5±2.12
Group II	277.33±8.80**	337±11.07**	378.83±11.85**
Group III	264.66±8.53#	196±7.10**	121.5±2.95**
Group IV	268.70±0.76	102.5±1.47**	97.16±0.70**
Group V	265.50±7.02#	98.5±10.67**	91.5±2.39**

Results are expressed as mean ±SEM;n=6; **=p<0.001 and # =not significant

Table 3: Effect of ECS on SGOT, SGPT and ALP levels in normal & experimental rats

Groups	SGOT (IU/L)		SGPT (IU/L)		ALP (IU/L)	
	0 day	45 th day	0 day	45 th day	0 day	45 th day
Group I	63.01±3.40	61.58±1.43	75.33±0.66	76±1.34	76±1.24	78.33±0.82
Group II	153.45±2.64**	223±3.50*	247.87±2.05**	145.57±6.67**	141.68±1.57**	207±1.17**
Group III	141.37±1.67#	101±1.28**	95.86±1.07**	143.33±1.89#	145.33±1.78#	93.4±1.53
Group IV	132.15±0.65	158.33±0.63**	125.89±55.3**	128.85±0.08	121.87±0.70	110.3±0.99**
Group V	109.37±3.77#	86±1.94#	107±2.17**	74.66±2.37#	127.60±2.34#	80.17±0.85**

Results are expressed as mean ± SEM; n=6; **=p<0.001 and # = not significant

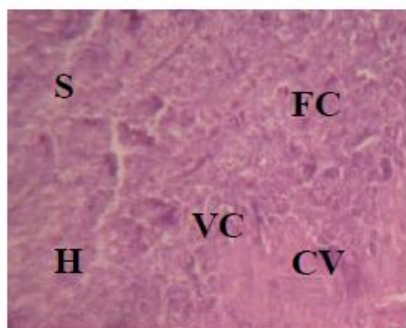


Figure (1A)

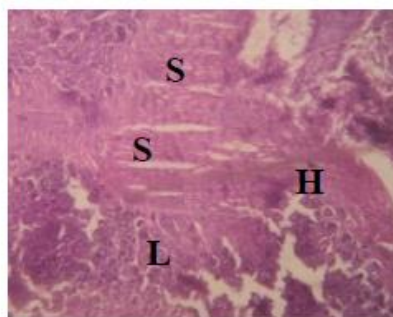


Figure (1B)

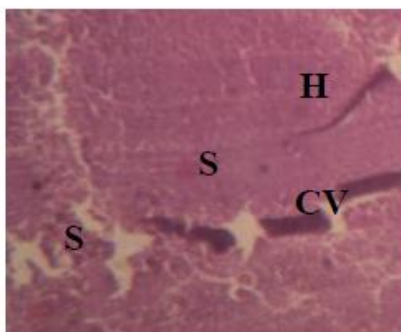


Figure (1C)

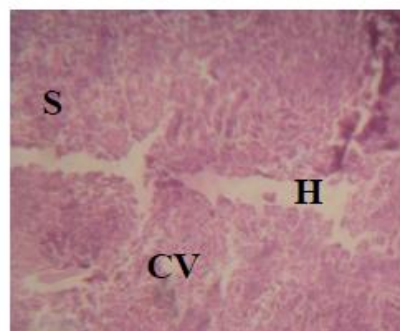


Figure (1D)

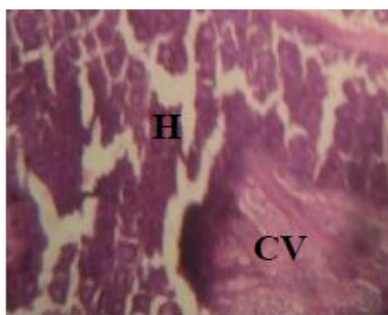


Figure (1E)

Cv-Central Vein; Vc-Vacuolation; Fc-Fatty Changes; H-Hepatocyte; S-Sinusoids

Figure 1A: Photomicrograph of Pancreas of normal control rat shows clear central vein, well-arranged hepatocytes and sinusoids. (H & E magnification X100)

Figure 1B: Photomicrograph of Pancreas of STZ induced diabetic rat shows congested central vein, fatty degeneration and cytoplasmic vacuolation. (H & E magnification X100)

Figure 1C: Photomicrograph of Pancreas of diabetic rat treated with Glibenclamide (5 mg/kg b.w) shows restoration of hepatocytes structure, clear sinusoids and reduction in fatty degeneration. (H & E magnification X100).

Figure 1D: Photomicrograph of Pancreas of diabetic rats treated with ECS (300 mg/kg b.w) shows well-arranged hepatocytes in between sinusoids, with a clear central vein. (H & E magnification X100)

Figure 1E: Photomicrograph of Pancreas of diabetic rat treated with ECS (500 mg/kg b.w.) shows restoration of hepatocytes structure to near normal, still little congestion of central vein seen. (H & E magnification X100)

The elevated SGOT, SGPT, ALP levels in STZ induced diabetic animals were significantly reduced ($p < 0.001$) in comparison with diabetic control (positive control) and Glibenclamide treated groups (Table 3). Meanwhile diabetic animals (group IV) treated with ECS 300 mg/kg b.w. showed no disturbances in the levels of plasma glucose, SGOT, SGPT, ALP in comparison with negative controls.

Further histopathological examination of pancreas sections of STZ diabetic rats showed marked hepatocyte necrosis, fatty degeneration, extensive vacuolization and distorted structure. Treatment with ECS restored the normal architecture of pancreas tissue in STZ diabetic rats, thereby proving its hepatoprotective role. No changes were found in the pancreas histopathology of normal rats treated with ECS, indicating its non-toxic nature. Treatment with glibenclamide also restored the mere normal architecture of pancreas tissue in STZ diabetic rats, but showed the presence of vascular congestion of the central vein and few hepatocyte nuclei vacuolization. These histopathological changes obtained in our study were indicating ECS is having act as an antidiabetic potential role.

DISCUSSION

In our study, diabetes was induced in rats by a single intraperitoneal injection of STZ at a dose of 45mg/kg b.w. and the anti-diabetic activity of ECS and its effect on pancreas histology function of study. DM is associated with progressive metabolic derangement, worsening glycemic control and morphological changes in the liver, pancreas and other organs⁹⁻¹⁰. The elevated levels of SGOT, SGPT in serum are an indication of damaged Pancreas tissue, administration of ECS improves the Pancreas function by decreasing the levels of SGOT, SGPT in diabetic treated rats, indicating its hepatoprotective effect. ALP acts as a marker for biliary function¹¹. In the study, diabetes was induced in rats by single intraperitoneal injection of STZ at a dose of 45 mg/kg b.w. and the histological basis of hepatoprotective activity of ACD 500 mg/kg b.w. was determined. Diabetes mellitus is associated with progressive metabolic derangement, worsening glycemic control, and morphological changes in the liver, pancreas and other organs^{9,12}. The blood glucose level in alloxan induced diabetic rats by an ethanolic extract due to decrease abdominal glucose absorption and recover extra pancreatic activity including the invigoration of peripheral glucose utilization or incitement of glycolytic glucose utilization process with conterminous decrease in glyconeogenesis¹³.

Liver production of important role in the monitoring and stabilizing glucose level so she could remain considered glucostat monitor. The results showed that injection of alloxan induces a hepatocellular damage, which remains indicated by a significant increase in AST, ALT and ALP in the diabetic group as compared to control groups. Elevated level showed that AST, ALT and ALP impaired liver function¹⁴. STZ-induced diabetes is characterized in an unembellished loss of body weight. Glibenclamide is regularly used as a standard antidiabetic drug in STZ-induced moderate diabetes to be compared with a variety of hypoglycemic compounds and its efficiency is recognized¹⁵⁻¹⁶. The elevation of liver biomarker enzymes, such as AST, ALT and ALP in diabetic control rats indicates that diabetes may induce hepatic dysfunction¹⁷. That liver was necrotized in diabetic patients. Therefore, the increment of the activities of AST, ALT and ALP in serum may be mainly due to the leakage of these enzymes after the liver cytosol into the blood stream¹⁸. Antidiabetic medicinal plants, despite the vast amount of progress, witnessed thus far, it is clear that further studies are required to clarify the potential antidiabetic effects of natural products.

CONCLUSION

Costus spicatus beneficial effects as both antidiabetic, antihyperglycemic agents and also warrants further study to isolate and characterize potent molecules for DM and its lipid associated complications. All these effects were observed on 45th day. The present experimental results indicated that ethanol extracts of *Costus spicatus* exhibited a potent Anti-hyperlipidaemic activity property in STZ induced diabetic rats. ECS and Glibenclamide of STZ induced diabetic animals restored the normal plasma glucose levels and SGOT, SGPT and ALP levels without damaging the pancreas.

CONFLICTS OF INTEREST:

The authors stated that no conflicts of interest.

REFERENCES

1. Tafesse T.B, Hymete A, Mekonnen Y, Tadesse M. Antidiabetic activity and phytochemical screening of extracts of the leaves of *Ajugaremba Benth* on alloxan-induced diabetic mice. *BMC Complementary and Alternative Medicine*. 2017; 17(243): 1-9.
2. Truss M, and Beato M. Steroid hormone receptors: interaction with deoxyribonucleic acid and transcription factors. *Endocrinol Rev*. 1993; 14: 450-79.
3. Lieberman BA. The estrogen receptor activity cycle: dependence on multiple protein-protein interaction. *Crit Rev In Endocr Gene Expr*. 1997; 7: 43-59.
4. Kinkar SB and Patil KG. Investigations on Insulin Levels and Blood Sugar Concentration in *Tinosporacordifolia* Extract Treated Albino Rats. *World Journal of Zoology*. 2016; 11(1): 155-158.
5. Zimmet P, Alberti KG, Shaw J. Global and societal implications of the diabetes epidemic. *Nature*; Dec. 2001; 414(6865): 782-787.
6. Haghvirdzadeh P, Mohamed Z, Abdullah NA. KCNJ11 genetic polymorphisms and risk of diabetes mellitus. *J Diabetes Res*. 2015; 908152.
7. Liu IM, Tzeng TF, Liou SS, Lan TW. Improvement of insulin sensitivity in obese Zucker rats by myricetin extracted from *Abelmoschus moschatus*. *Planta Med*. 2007; 73, 1054-1060.
8. Jothive N, Ponnusamy SP, Appachi M, Singaravel S, Rasilingam D and Devasigamani K. Anti-diabetic activity of methanol leaf extract of *Costus spicatus* D. Don in alloxan-induced diabetic rats. *J Health Sci*. 2007; 53(6): 655-663.

9. Cook MN, Girman CJ, Stein PP, Alexander CM, Holman RR. Glycaemic control continues to deteriorate after sulfonylurea are added to metformin among patients with type 2 diabetes. *Diabetes Care*. 2005; 28: 995-1000.
10. Cristina L, Roberto L, Stefano DP. Beta cell failure in type 2 diabetes mellitus. *CurrDiab Rep*. 2005; 8:179-184.
11. SanthoshKumar S. Protective effect of *Cynodondactylon* against STZ induced hepatic injury in rats. *J EcophysiolOccupHlth*. 2008; 8:195-199.
12. Cristina L, Roberto L, Stefano DP. Beta cell failure in type 2 diabetes mellitus. *CurrDiab Rep*. 2008; 8:179-184.
13. Hua V. Lin and Domenico Accili. Hormonal Regulation of Hepatic Glucose Production In Health And Disease. *Cell Metab*. 2011; 6; 14(1): 9-19.
14. Preetha, P.P. Girija Devi, V: Rajamohan T. Comparative effects of mature coconut water (*Cocosnucifera*) and glibenclamide on some biochemical parameters in alloxan induced diabetic rat. *Revista Brasileira de Farmacognosia Brazilian Journal of Pharmacognosy*. 2013; 23(3): 481-487.
15. Andrade Cetto A, Wiedenfeld H. Hypoglycemic effect of *Cecropia obtusifolia* on streptozotocin diabetic rats. *J. Ethnopharmacol*. 2001; 78: 145-149.
16. Paredes A, Hasegawa M, Prieto F, Mendez J, Rodríguez M, Rodríguez-Ortega M: Biological activity of *Guatteriacardoniana* fractions. *J Ethnopharmacol*. 2001; 78: 129-132.
17. Rathod NR, Raghuvver I, Chitme HR, Chandra R. Free radical scavenging activity of *Calotropis gigantea* on streptozotocin-induced diabetic rats. *Indian J Pharm Sci*. 2009; 71:615-621.
18. Navarro CM, Montilla PM, Martin A, Jimenez J, Utrilla PM. Free radicals scavenger and antihepatotoxic activity of *Rosmarinus*. *Plant Medicine*. 1993; 59: 312-314.

