

Open  Access

Research Article

A simple randomized comparative study to evaluate the efficacy of 0.7% w/v Olopatadine hydrochloride ophthalmic solution and the Fixed Dose Combination of 0.1% w/v Olopatadine hydrochloride and 0.4% w/v Ketorolac tromethamine ophthalmic solution for the treatment of allergic conjunctivitis

Anup Jagarlamudi ¹, E. Anushree ², Soma Harika ², K. Kavya Sri ², Ch. Rohit ²¹ Associate Professor Department of Pharmacy Practice KVK college of pharmacy, Hyderabad, 501512-India² Fifth year Pharm.D. KVK college of Pharmacy, Hyderabad, 501512-India

ABSTRACT

Conjunctivitis is defined as the inflammation of the conjunctiva. Allergic conjunctivitis is an acute, intermittent or chronic inflammation of the conjunctiva due to air borne allergens. Allergic reactions occur when the immune system is hypersensitive to normally harmless environmental substances, called allergens. Allergic conjunctivitis is an increasingly prevalent allergic reaction and currently 40% of global population is suffering from allergic conjunctivitis. Being an immunopathological disease, Conjunctival mast cell degranulation plays a major role in ocular allergic disease and so treatment options should be concentrated on preventing degranulation or of antagonizing the effects of the primary mediator, histamine. Commonly used medications are: Topical OTC antihistamines (eg, ketotifen), topical prescription antihistamines (eg, olopatadine, bepotastine, alcaftadine), NSAIDs (eg, ketorolac), or mast cell stabilizers (eg, nedocromil, cromolyn, azelastine) and can be used separately or in combination. In our study, the safety profile of Olopatadine 0.7% is comparable with fixed dose combination of Olopatadine 0.1% and ketorolac tromethamine 0.4% by assessing the reduction in the severity of four parameters (ocular itching, conjunctival hyperemia, chemosis and tearing) of allergic conjunctivitis over 14 days of daily treatment. Ours is a Prospective case observational study conducted from August 2018-January 2019. A total of 80 patients were screened from the ophthalmology outpatient department. All the subjects who fulfilled eligibility criteria were randomly assigned in equal proportions into two arms i.e, group-1(patients receiving 0.7% olopatidine Hcl eye drops) & group-2(patients receiving 0.1% olopatidine Hcl+ 0.4% ketorolac tromethamine eye drops.). After the duration of treatment, the outcomes of the therapy were assessed and statistical analysis was done. It was observed that there was a significant difference in the percentage reduction of all the four parameters in the group 1 (i.e; patients treated with monotherapy) than the group 2 (i.e; patients treated with combination therapy). Also, the statistically obtained p value of the mean scores of final visits of four parameters were significantly lower in the first group than the second group from the second day through to the end of the study ($p < 0.05$). From this we concluded that monotherapy of 0.7% Olopatadine hydrochloride ophthalmic solution was found to be more effective in reducing the clinical signs and symptoms of allergic conjunctivitis than dual combination therapy of 0.1% Olopatadine hydrochloride + 0.4% Ketorolac tromethamine ophthalmic solution.

Keywords: Conjunctivitis, Olopatadine, Ketorolac, Chemosis, combination therapy.

Article Info: Received 25 March 2019; Review Completed 02 May 2019; Accepted 06 May 2019; Available online 15 May 2019



Cite this article as:

Jagarlamudi A, Anushree E, Harika S, Kavya Sri K, Rohit C, A simple randomized comparative study to evaluate the efficacy of 0.7% w/v Olopatadine hydrochloride ophthalmic solution and the Fixed Dose Combination of 0.1% w/v Olopatadine hydrochloride and 0.4% w/v Ketorolac tromethamine ophthalmic solution for the treatment of allergic conjunctivitis, Journal of Drug Delivery and Therapeutics. 2019; 9(3):279-285 <http://dx.doi.org/10.22270/jddt.v9i3.2657>

*Address for Correspondence:

Dr. Anup Jagarlamudi, M.Pharm., Ph.D., Associate Professor, Department of Pharmacy Practice, KVK college of pharmacy, Surmaiguda, Near Ramoji Film City, RR district, Hyderabad, Telengana. 501512.

INTRODUCTION

Conjunctivitis is defined as the inflammation of the conjunctiva. The conjunctiva is a thin membrane that lines the inner surface of the eyelids and sclera. Conjunctivitis can affect children and adults. Allergic conjunctivitis is acute, intermittent or chronic inflammation of the conjunctiva due to air borne allergens. Allergic reactions occur when the immune system is hypersensitive to normally harmless environmental substances, called allergens. Allergic conjunctivitis is caused by airborne allergens that come in

contact with the eye e.g. pollen, cat/dog hair and moulds. Allergic conjunctivitis occurs very frequently and is seen most commonly in areas with high seasonal allergen and pollen counts. [1]

Eye inflammation most commonly occurs in response to infection, allergy, surgery or trauma (i.e., blow to the eye, foreign body, chemical injury). It is important to control the duration and severity of inflammation and avoid scarring, as even a small amount of scarring of eye tissue can lead to irreversible vision impairment. An eye inflammatory

response is a generalized reaction to stimuli that typically fall into two classes: foreign substances such as bacteria or allergens or injuries to the eye tissue caused by trauma or surgery. Although inflammatory reactions commonly occur as part of the body's response to bacterial or viral infection, inflammation can also occur in the absence of infection. Allergens such as pollen, house dust or insect stings may provoke inflammation. Eye surgery is another, and perhaps the most common, cause of eye inflammation. Doctors naturally expect their patients to suffer eye inflammation as a direct result of eye surgery and, as such, treat their patients in advance for this outcome.^[1, 2]

Types:

Allergic conjunctivitis may be divided into 5 major subcategories.

1. Acute Allergic Conjunctivitis (AAC)
2. Intermittent/Seasonal Allergic Conjunctivitis (IAC/SAC)
3. Persistent/Perennial Allergic Conjunctivitis (PAC)
4. Vernal Kerato conjunctivitis (VKC)
5. Atopic Kerato conjunctivitis (AKC)
6. Giant Papillary Conjunctivitis (GPC)

Early diagnosis and treatment will help prevent the rare complications that can occur with this disease.^[2, 3]

Causes:

Among the most common allergens that cause conjunctivitis are:

- Pollen from trees, grass and ragweed
- Animal skin and secretions such as saliva
- Perfumes
- Cosmetics
- Skin medicines
- Air pollution
- Smoke
- Dust mites
- Balsam of Peru (used in food and drink for flavouring, in perfumes and toiletries for fragrance, and in medicine and pharmaceutical items for healing properties)

Allergic conjunctivitis is due to a type I hypersensitivity reaction to a specific antigen.

Seasonal allergic conjunctivitis (hay fever conjunctivitis) is caused by airborne mold spores, or pollen of trees, grasses, or weeds. It tends to peak during the spring, late summer, or early fall and disappear during the winter months—corresponding to the life cycle of the causative plant.

Perennial allergic conjunctivitis (atopic conjunctivitis, atopic kerato conjunctivitis) is caused by dust mites, animal dander, and other non seasonal allergens. These allergens, particularly those in the home, tend to cause symptoms year-round.

Vernal kerato conjunctivitis is a more severe type of conjunctivitis most likely allergic in origin. It is most

common among males aged 5 to 20 who also have eczema, asthma, or seasonal allergies. Vernal kerato conjunctivitis typically reappears each spring and subsides in the fall and winter. Many children outgrow the condition by early adulthood.

Some people may also experience allergic conjunctivitis in reaction to certain medications or substances dropped into the eyes, such as contact lens solution or medicated eye drops.^[4,6]

Pathophysiology:

Allergic conjunctivitis is caused by an allergen-induced inflammatory response in which allergens interact with IgE bound to sensitized mast cells resulting in the clinical allergic expression. The pathogenesis of allergic conjunctivitis is predominantly an IgE-mediated hypersensitivity reaction. Activation of mast cells induces enhanced tear levels of histamine, tryptase, prostaglandins and leukotrienes. This immediate or early response lasts clinically 20–30 min.

Mast cell degranulation also induces activation of vascular endothelial cells, which in turn expresses chemokines and adhesion molecules such as intercellular adhesion molecule (ICAM), vascular cell adhesion molecule (VCAM). Other chemokines secreted include regulated upon activation normal T cell expressed and secreted (RANTES) chemokines, monocyte chemo attractant protein (MCP), interleukin (IL)-8, eotaxin, macrophage inflammatory protein (MIP)-1 alpha.

These factors initiate the recruitment phase of inflammatory cells in the conjunctival mucosa, which leads to the ocular late-phase reaction^[5-8]

Symptoms:

The most common symptoms of allergic conjunctivitis include a red eye and discharge. Other signs and symptoms of conjunctivitis inflammation are itching, redness, swelling, pain, tearing, heat and redness, photosensitivity, foreign body sensation. Itching is the most frequent symptom and is considered the hallmark of ocular allergy.^[1]

Treatment:

There are a number of treatments available for the symptoms of allergic conjunctivitis. In addition, basic eye care is important.

Basic Eye Care:

- Avoid rubbing the eyes. If itching is bothersome, use artificial tears, a cool compress, or antihistamine eye drops.
- Minimize exposure to pollen by staying inside when possible, using air conditioning, and keeping car and home windows closed during the peak allergy seasons.
- People with year-round allergic conjunctivitis should consider consulting an allergy specialist to determine which allergens are responsible for their symptoms (e.g. dust mites, cat dander, and others).

Medications:

People with sudden onset symptoms can use a combination antihistamine/ vasoconstrictor eye drop four times daily for up to two weeks.

People with seasonal or year-round symptoms are usually treated with a combination antihistamine/mast cell-stabilizer eye drops. Most of these require a prescription.

An oral antihistamine may be most helpful when it is taken preventively (before symptoms develop). However, antihistamines may also be used to treat symptoms after they have started, although the greatest benefit may not be seen for several days.

Non-sedating oral antihistamines include olopatadine hydrochloride, fexofenadine, Loratadine, Desloratadine, Cetirizine, and Levocetirizine.

NSAIDs like ketorolac tromethamine can also be used in the treatment of allergic conjunctivitis.

Diphenhydramine is a short-acting, sedating antihistamine that can be taken at bedtime to reduce night-time itching.

Avoidance of known allergens, cold compresses, and use of tear supplements can reduce symptoms of allergic conjunctivitis; antigen desensitization is occasionally helpful.

Topical OTC antihistamines (eg, ketotifen) are useful for mild cases. If these drugs are insufficient, topical prescription antihistamines (eg, olopatadine, bepotastine, alcaftadine), NSAIDs (eg, ketorolac), or mast cell stabilizers (eg, nedocromil, cromolyn, azelastine) can be used separately or in combination.

Topical corticosteroids (eg, loteprednol, fluorometholone 0.1%, prednisolone acetate 0.12% to 1% drops tid) can be useful in recalcitrant cases.

Because topical corticosteroids can exacerbate ocular herpes simplex virus infections (see Herpes Simplex Keratitis), possibly leading to corneal ulceration and perforation and, with long-term use, to glaucoma and possibly cataracts, their use should be initiated and monitored by an ophthalmologist.

Topical cyclosporine may be helpful. Oral antihistamines (eg, fexofenadine, cetirizine, or hydroxyzine) can be helpful, especially when patients experience other allergic symptoms (eg, rhinorrhea).^[1,4]

Olopatadine Hydrochloride:

Olopatadine hydrochloride ophthalmic solution has been available in concentrations of 0.1%, 0.2% and 0.7% for the treatment of allergic conjunctivitis and itching associated with allergic conjunctivitis.^[9]

Indication:

Olopatadine hydrochloride ophthalmic solution treatment of ocular itching associated with allergic conjunctivitis.^[9]

Description:

Olopatadine hydrochloride ophthalmic solution is a sterile ophthalmic solution containing olopatadine for topical administration to the eyes. Olopatadine hydrochloride is a white, crystalline, water-soluble powder with a molecular weight of 373.88 and a molecular formula of $C_{21}H_{23}NO_3 \cdot HCl$.^[10]

The Chemical Name: 11-[[[Z]-3(dimethylamino)propylidene]-6-11dihydrodibenz [b,e] oxepin-2- acetic acid, hydrochloride.^[11]

Each mL of solution contains an active ingredient [7.76 mg of olopatadine hydrochloride (7 mg olopatadine)] and the following inactive ingredients: povidone; hydroxypropyl-gamma-cyclodextrin; polyethylene glycol 400; hydroxypropyl methylcellulose; boric acid; mannitol; benzalkonium chloride 0.015% (preservative); hydrochloric

acid/sodium hydroxide (to adjust pH); and purified water.^[11]

Ophthalmic solution has a pH of approximately 7.2 and an osmolality of approximately 300 m Osm /kg.^[11]

Mechanism of Action:

Olopatadine is a mast cell stabilizer and a histamine H1 antagonist. Decreases chemotaxis and also inhibits eosinophil activation.^[10]

Dosage Forms and Strengths:

Ophthalmic solution:

7.76 mg of olopatadine hydrochloride in one mL solution (0.7%) in a 4 mL bottle. ^[11]

Dosage and Administration:

The recommended dose is one drop in each affected eye once a day.^[10]

Adverse Reactions:

Symptoms similar to cold syndrome and pharyngitis were reported at an incidence of approximately 10%.

Headaches have been reported at an incidence of 7%.

The following adverse experiences have been reported in 5% or less of patients:

Ocular: blurred vision, burning or stinging, conjunctivitis, dry eye, foreign body sensation, hyperemia, hypersensitivity, keratitis, lid edema, pain and ocular pruritus.

Non-ocular: asthenia, back pain, flu syndrome, headache, increased cough, infection, nausea, rhinitis, sinusitis and taste perversion.^[10,12]

Ketorolac Tromethamine:

Ketorolac tromethamine ophthalmic solution is a member of the pyrrolopyrrole group of nonsteroidal anti-inflammatory drugs (NSAIDs) for ophthalmic use.

Ketorolac tromethamine ophthalmic solution is supplied as a sterile isotonic aqueous solution, with a pH of approximately 7.4.

Ketorolac tromethamine ophthalmic solution is a racemic mixture of R-(+) and S-(-) ketorolac tromethamine. Ketorolac tromethamine may exist in three crystal forms. All forms are equally soluble in water. The pKa of ketorolac is 3.5.

This white to off-white crystalline substance discolors on prolonged exposure to light. The osmolality of ophthalmic solution is approximately 290 m Osm/kg.^[15]

Clinical Pharmacology:

Mechanism of Action:

Ketorolac tromethamine is a nonsteroidal anti-inflammatory drug which, when administered systemically, has demonstrated analgesic, anti-inflammatory, and anti-pyretic activity. The mechanism of its action is thought to be due to its ability to inhibit prostaglandin biosynthesis.

Indications And Usage:

Ketorolac tromethamine ophthalmic solution is indicated for the reduction of ocular pain and burning/stinging.

Contraindications:

Ketorolac tromethamine ophthalmic solution is contraindicated in patients with previously demonstrated hypersensitivity to any of the ingredients in the formulation.

Adverse Reactions:

The most frequently reported adverse reactions for ophthalmic solution occurring in approximately 1 to 5% of the overall population were conjunctival hyperemia, corneal infiltrates, headache, ocular edema and ocular pain.

The most frequent adverse events reported with the use of ketorolac tromethamine ophthalmic solutions have been transient stinging and burning on instillation. These events were reported by 20% - 40% of patients participating in these other clinical trials. Other adverse events occurring approximately 1% - 10% of the time during treatment with ketorolac tromethamine ophthalmic solutions included allergic reactions, corneal edema, iritis, ocular inflammation, ocular irritation, ocular pain, superficial keratitis, and superficial ocular infections. [14]

Dosage and Administration:

The recommended dose of ophthalmic solution is one drop two times a day in the effected eye.

Pharmacokinetics Two drops of 0.4% ketorolac tromethamine ophthalmic solution instilled into the eyes of patients. [13]

Aims & Objectives:

The aim of the study is to evaluate the efficacy of 0.7 % w/v Olopatadine Hydrochloride Ophthalmic Solution and the fixed dose combination of 0.1% w/v Olopatadine Hydrochloride and 0.4% w/v ketorolac tromethamine Ophthalmic Solution for the treatment of Allergic Conjunctivitis.

Primary Objective:

To evaluate the efficacy of 0.7% w/v Olopatadine Hydrochloride Ophthalmic Solution compared with 0.1% w/v Olopatadine Hydrochloride and 0.4% w/v ketorolac tromethamine Ophthalmic Solution for the treatment of Allergic Conjunctivitis through four parameters of allergic conjunctivitis {ocular itching, conjunctival hyperemia , chemosis and tearing}.

Secondary Objective:

Change from baseline in ocular itching score on day 2 [at 24 hrs (± 1 hr) post first instillation of eye drops], day 7 (± 1 day) and day 14 (± 1 day)

Change from baseline in conjunctival hyperemia score on days 2 [at 24 hrs (± 1 hr) post first instillation of eye drops], 7 (± 1 day) and 14 (± 1 day).

Change from baseline in tearing score on days 2 [at 24 hrs (± 1 hr) post first instillation of eye drops], 7 (± 1 day) and 14 (± 1 day).

Change from baseline in chemosis score on days 2 [at 24 hrs (± 1 hr) post first instillation of eye drops], 7 (± 1 day) and 14 (± 1 day).

To measure the outcomes following scales are used

- Ocular Itching Scale
- Conjunctival Hyperemia Scale
- Tearing Scale
- Chemosis Scale

MATERIALS AND METHODS

Study Site: Outpatient department of Ophthalmology, Gandhi Hospital, Secunderabad.

Study Period: August 2018-January 2019

Study Duration: 6months

Study Design: Prospective case observational study

Study Disease: Allergic Conjunctivitis

Study approval: Project is approved by Institutional Review Board.

Sample size (N) : 80 subjects

STUDY METHOD:

- Preparation of structured documentation form for documentation of study cases (Annexure-1) and the informed consent form (Annexure-2) for patient consent.
- Visit outpatient department on regular basis.
- Review & collection of cases according to inclusion and exclusion criteria on regular basis.
- Explain about the study to the patient and his/her attenders and seeking their consent to participate in the study.
- Randomly providing the medications and explaining regarding the dose to be administrated.
- Seeking their contact numbers for follow up process.
- Collection of data.
- Interpretation of data to generate result.
- Analysis of result to obtain the final outcome by statistical application and submission

Inclusion Criteria:

- ✚ Male or female subjects, aged 10 years to 70 years (both inclusive).
- ✚ Subjects with diagnosis of ocular itching associated with allergic conjunctivitis in one or both the eyes.
- ✚ Subjects willing to discontinue contact lens wear for at least 72 hours prior to instillation of eye drops.

Exclusion Criteria:

- ✚ Subjects with any contraindications or hypersensitivities to the use of the study medication or their components.
- ✚ Subjects who are blind or subjects with single eye will be excluded from the study.
- ✚ Patients with Visual acuity of 20/80 in any eye.
- ✚ Subjects with known case of persistent dry eye syndrome or currently on treatment for dry eyes.
- ✚ Subjects with Vernal Kerato-conjunctivitis (VKC), Atopic Kerato-conjunctivitis (AKC) and Giant Papillary Conjunctivitis (GPC) will be excluded from the study.

Over all Study Design:

A simple randomised comparative study to evaluate the efficacy of 0.7% w/v Olopatadine Hydrochloride Ophthalmic Solution compared with fixed dose combination of 0.1% w/v

Olopatadine Hydrochloride and 0.4%w/v ketorolac tromethamine Ophthalmic Solution for the treatment of Allergic Conjunctivitis. During the screening, subjects who gave consent are evaluated for all the eligibility criteria.

Eligible subjects clinically diagnosed with ocular itching associated with allergic conjunctivitis and who are between 10 to 70 years of age are considered for the study. Subjects fulfilling all the inclusion criteria and none of the exclusion criteria are randomized on day 1.

Subjects are assigned one of the two groups i.e. Group 1 or Group 2 consisting of 0.7% olopatadine hydrochloride or fixed dose combination of 0.1% olopatadine and 0.4% ketorolac tromethamine respectively. Subjects who are categorised under group 1 are instructed to instil one drop in each affected eye once a day and subjects who are categorised under group 2 are instructed to instil one drop in each effected eye twice a day. Subjects are instructed to instil first drop at site in front of the principal investigator on the day of randomization.

Subject is assessed for ocular itching, conjunctival hyperemia, tearing and chemosis during the entire study period. Physical examination and vitals are taken at all the visits till the end of study. Adverse events and concomitant medications are also assessed from Baseline to visit 3/end of study visit. Visual acuity test and slit lamp biomicroscopy was conducted on baseline visit.

All subjects are assessed for primary endpoint i.e. Change from baseline in ocular itching score on days 2 (at 24 hrs (± 1 hr) post first instillation of eye drops), 7 and 14, secondary endpoint i.e. Change from baseline in conjunctival hyperemia grade on day 2 (at 24 hrs (± 1 hr) post first instillation of eye drops), 7 and 14, Change from baseline in tearing score at the end of days 2 (at 24 hrs (± 1 hr) post first instillation of eye drops), 7 and 14, Change from baseline in chemosis score at the end of day 2 (at 24 hrs (± 1 hr) post first instillation of eye drops), 7 and 14 and At the final visit overall response of clinical cure & overall assessment is done by Patients and Physician. Subjects are assessed for the efficacy of both the study medications.

Statistical Analysis:

Descriptive statistical analysis has been carried out in the present study whenever necessary.

RESULTS

A total of 80 patients with allergic conjunctivitis were assigned one of the two groups i.e. Group 1 or Group 2 consisting of 0.7% olopatadine hydrochloride or fixed dose combination of 0.1% olopatadine and 0.4% ketorolac tromethamine during the corresponding time period of August 2018-January 2019.

Table-1: Distribution of Patients on the basis of Age.

S.no	Age	No. of Patients
1	11-20	2
2	21-30	22
3	31-40	21
4	41-50	24
5	51-60	10
6	61-70	1

DISTRIBUTION OF PATIENTS ON THE BASIS OF GENDER

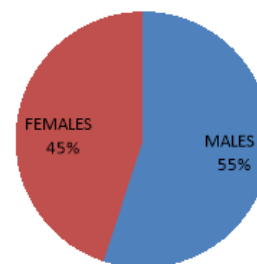


Fig-1: Distribution of patients on the basis of Gender.

Total sample Size: N=80,

40 patients were treated with monotherapy (Olopatadine Hcl 0.7%w/v) and 40 patients were treated with dual combination therapy (Olopatadine Hcl 0.1% w/v+ Ketorolac tromethamine 0.4%w/v).

Group-1 consists of 40 patients who are treated with 0.7% w/v olopatadine hydrochloride ophthalmic solution. The mean ocular itching scores of these patients on baseline, second visit and final visit are - 3.5125, 1.9375 and 0.3250 respectively.

The mean conjunctival hyperemia scores of Group-1 patients on baseline, second visit and final visit are - 3.15, 1.6375 and 0.3250 respectively.

The mean chemosis scores of Group-1 patients on baseline, second visit and final visit are- 2.9250, 1.0750 and 0.20 respectively.

The mean tearing scores of Group-1 patients on baseline, second visit and final visit are- 2.9250, 1.0750 and 0.20 respectively.

Group-2 consists of 40 patients who are treated with olopatadine hydrochloride 0.1% w/v + ketorolac tromethamine 0.4 % w/v ophthalmic solution.

The mean ocular itching scores of Group-2 patients on baseline, second visit and final visit are- 3.6875, 2.43 and 0.9250 respectively.

The mean conjunctival hyperemia scores of Group-2 patients on baseline, second visit and final visit are- 3.57, 2.3750 and 0.850 respectively.

The mean chemosis scores of Group-2 patients on baseline, second visit and final visit are- 2.9625, 1.7250 and 0.650 respectively.

The mean tearing scores of Group-2 patients on baseline, second visit and final visit are- 2.8520, 1.5750 and 0.65 respectively.

Table 2: Percentage Reduction in Severity of Allergic Conjunctivitis Parameters at the end of the study from Baseline:

Parameters	Monotherapy	Combinational Therapy
Ocular itching	90.74%	74%
Conjunctival hyperemia	89.7%	76%
Chemosis score	93%	78.05%
Tearing score	100%	76.9%

DISCUSSION

By comparing the treatment outcomes of both Group-1 and Group-2 for the study period, i.e. from baseline to final visit of treatment, the following observations are made:

- ✓ It was observed that 52.5% of patients had a complete cure of ocular itching when treated with 0.7% olopatadine hydrochloride eye drops while 12.5% of patients had a complete cure of ocular itching when treated with FDC of 0.1% olopatadine hydrochloride and 0.4% ketorolac tromethamine eye drops.
- ✓ About 67.5% of patients had a complete cure of conjunctival hyperemia when treated with 0.7% olopatadine hydrochloride eye drops while 12.5% of patients had a complete cure of conjunctival hyperemia when treated with FDC of 0.1% olopatadine hydrochloride and 0.4% ketorolac tromethamine eye drops.
- ✓ In case of chemosis score 80% of patients had a complete cure when treated with 0.7% olopatadine hydrochloride eye drops while 42.5% of patients had a complete cure of chemosis when treated with FDC of 0.1% olopatadine hydrochloride and 0.4% ketorolac tromethamine eye drops.
- ✓ It was observed that 100% of patients had a complete cure of tearing when treated with 0.7% olopatadine hydrochloride eye drops while 35% of patients had a complete cure of tearing when treated with FDC of 0.1% olopatadine hydrochloride and 0.4% ketorolac tromethamine eye drops
- ✓ In our study the ADR that we observed was headache in about 2.4% of our total population(80 patients). The concomitant medication prescribed by the physician was Paracetamol 325mg BD.

When the clinical parameters of eyes treated with 0.7% Olopatadine Hcl were compared with those treated with FDC of 0.1% Olopatadine Hcl and 0.4% Ketorolac promethazine:

- The mean scores of ocular itching was found to be lower in 0.7% Olopatadine Hcl (0.3250) compared to 0.1% Olopatadine Hcl and 0.4% Ketorolac tromethamine (0.9250).
- The mean scores of conjunctival hyperemia was found to be lower in 0.7% Olopatadine Hcl (0.3250) compared to 0.1% Olopatadine Hcl and 0.4% Ketorolac tromethamine (0.850).
- The mean scores of chemosis was found to be lower in 0.7% Olopatadine Hcl (0.20) compared to 0.1% Olopatadine Hcl and 0.4% Ketorolac tromethamine (0.650).
- The mean scores of tearing was found to be lower in 0.7% Olopatadine Hcl (0) compared to 0.1% Olopatadine Hcl and 0.4% Ketorolac tromethamine (0.65).

Also when the percentage reduction in the severity of all the four parameters were compared in both groups i.e. patients treated with mono and combination therapy, the following outcomes were observed:

- In case of monotherapy, the percentage reduction in the severity of ocular itching score was 90.74% whereas the percentage reduction in the severity of

ocular itching in case of combinational therapy was 74%.

- The percentage reduction in the severity of conjunctival hyperemia score in monotherapy was 89.7% whereas the percentage reduction in the severity of conjunctival hyperemia in case of combinational therapy was 76.1%.
- In case of monotherapy, the percentage reduction in the severity of chemosis score was 93.1% whereas the percentage reduction in the severity of chemosis in case of combinational therapy was 78.05%.
- The percentage reduction in the severity of tearing score in monotherapy was 100% whereas the percentage reduction in the severity of tearing score in case of combinational therapy was 76.9%.

These observations indicate that there was a significant difference in the percentage reduction of all the four parameters in the group 1 (i.e; patients treated with monotherapy) than the group 2 (i.e; patients treated with combination therapy).

The statistically obtained *p* value of the mean scores of final visits of both groups was 0.001. Thus the scores of four parameters (ocular itching, conjunctival hyperemia, chemosis and tearing) were significantly lower in the first group i.e patients who received monotherapy than the second group i.e patients who received combinational therapy from the second day through to the end of the study (*p* < 0.05).

CONCLUSION

Both the monotherapy of 0.7% Olopatadine hydrochloride and dual combination therapy of 0.1% Olopatadine hydrochloride + 0.4% Ketorolac tromethamine ophthalmic solution were found to be effective in alleviating the clinical signs and symptoms of allergic conjunctivitis. However by comparing the parameters of allergic conjunctivitis in both the study Groups such as ocular itching, conjunctival hyperemia, chemosis and tearing, monotherapy of 0.7% Olopatadine hydrochloride ophthalmic solution was found to be more effective in reducing the clinical signs and symptoms of allergic conjunctivitis than combination therapy of 0.1% Olopatadine hydrochloride + 0.4% Ketorolac tromethamine ophthalmic solution.

ACKNOWLEDGEMENT

We would like to express our gratitude to everyone who was instrumental in this study. Our sincere thanks to Dr. Santha, Ophthalmologist, Gandhi Hospital, Secunderabad.

ABBREVIATIONS USED

AA-ACUTE ALLERGIC CONJUNCTIVITIS
 AKC-ATOPIC KERATO CONJUNCTIVITIS
 eg.-EXAMPLE
 FDC-FIXED DOSE COMBINATION
 GPC-GIANT PAPILLARY CONJUNCTIVITIS
 H₁-HISTAMINE 1 RECEPTOR
 HCl-HYDROCHLORIC ACID
 IAC/SAC-INTERMITTENT/SEASONAL ALLERGIC
 CONJUNCTIVITIS
 ICAM-INTERCELLULAR ADHESION MOLECULE
 IgE-IMMUNOGLOBULIN E
 IL- INTERLEUKIN
 MCP-MONOCYTE CHEMO ATTRACTANT PROTEIN
 Mg-MILLI GRAM
 MIP-MACROPHAGE INFLAMMATORY PROTEIN

ml.-MILLI LITERS
 NSAIDS-NON STEROIDAL ANTI INFLAMMATORY DRUGS
 Osm/kg-OSMATIC CONCENTRATION/KILO GRAM
 PAC-PERSISTENT/PERENNIAL ALLERGIC CONJUNCTIVITIS
 pH-POTENTIAL/POWER/CONCENTRATION OF HYDROGEN
 pKa-ACID DISSOCIATION CONSTANT
 RANTES-REGULATED UPON ACTIVATION NORMAL T CELL
 EXPRESSED AND SECRETED
 SAC-SEASONAL ALLERGIC CONJUNCTIVITIS
 V-VOLUME
 VCAM-VASCULAR CELL ADHESION MOLECULE
 VKC-VERNAL KERATO CONJUNCTIVITIS
 w/v-WEIGHT / VOLUME

REFERENCES

1. Pazeo (olopatadine hydrochloride ophthalmic solution 0.7%), Product Monograph, Alcon Canada, October 27 2016.
https://pdf.hres.ca/dpd_pm/00038554.PDF.
2. Pazeo (olopatadine hydrochloride ophthalmic solution 0.7%). Alcon. FDA Label.
https://www.accessdata.fda.gov/drugsatfda_docs/label/2015/206276s000lbl.pdf.
3. Bielory L. and Friedlaender M.H. Allergic Conjunctivitis . Immunol Allergy Clin North Am. 2008; 28(1): 43-58
4. Allergic Conjunctivitis (Medscape).
<http://emedicine.medscape.com/article/1191467-overview#a4>.
5. Ono S.J. and Abelson M.B. Allergic conjunctivitis: update on pathophysiology and prospects for future treatment. J. Allergy Clin. Immunol. 2005; 115 (1): 118-22.
6. Conjunctivitis (inflammation of the eye).
<http://www.netdoctor.co.uk/conditions/eyes/a5325/conjunctivitis-inflammation-of-the-eye/>.
7. Allergic Conjunctivitis (Uptodate).
<http://www.uptodate.com/contents/allergic-conjunctivitis-beyond-the-basics>.
8. Allergic conjunctivitis: a comprehensive review of the literature-NCBI-NIH
<https://www.ncbi.nlm.nih.gov/pmc/articles/PMC/3640929/>
9. <https://www.fda.gov/downloads/AdvisoryCommittees/CommitteesMeetingMaterials/PediatricAdvisoryCommittee/UCM591613.pdf>
10. https://www.accessdata.fda.gov/drugsatfda_docs/label/2010/021545s013lbl.pdf
11. https://www.accessdata.fda.gov/drugsatfda_docs/label/2015/206276s000lbl.pdf
12. https://www.accessdata.fda.gov/drugsatfda_docs/label/2003/20688slr016_patanol_lbl.pdf
13. https://www.accessdata.fda.gov/drugsatfda_docs/label/2003/21528_acular_lbl.pdf
14. https://www.accessdata.fda.gov/drugsatfda_docs/label/2012/022427s004lbl.pdf
15. Kothanda Raman ThyagaRajan . Combination of a non-steroidal anti inflammatory drug with an antihistaminic drug intended for ophthalmic use: US Patent App. 13/866, 313, 2013

JDDDT