




Journal of Drug Delivery and Therapeutics

Open Access to Pharmaceutical and Medical Research

© 2011-18, publisher and licensee JDDT, This is an Open Access article which permits unrestricted non-commercial use, provided the original work is properly cited

Open  Access

Research Article

Extraction and wound healing potential of *Nerium Indicum M*, *Artocarpus Heterophyllus Lam*, *Murraya Koenigii L*, *Punica Granatum L* on albino rats using burn wound model

Renuka Shukla, Varsha Kashaw*

SVN Institute of Pharmaceutical Sciences, Swami Vivekanand University, Sagar, Madhya Pradesh, India

ABSTRACT

Objective: The objective of present work was to extract the active constituents and evaluate the wound healing potential of *Nerium indicum*, *Artocarpus heterophyllus*, *Murraya koenigii*, *Punica granatum* on albino rats using burn wound model. Poly-herbal ointment and gel formulation was developed and compare with the extract of all plants. These plants has shown anti-asthmatic, anti-diabetic, anti-inflammatory, anti-microbial, anti-leukemic, anti-mycobacterial, antibacterial, antioxidant, antiulcer, antiviral, anticancer, antimalarial, anti-inflammatory and wound healing properties. **Materials and Methods:** Solvent extraction method has been utilized for the separation of the active constituents of interest by using 70% ethanol as a solvent. Poly-herbal ointment and gel formulations has been prepared by mixing the extract of *Nerium Indicum*, *Artocarpus heterophyllus*, *Murraya koenigii* and *Punica granatum* in different ratio with the ointment base (10-15%) contains PEG and for gel formulation Carbapol-940 base (10-15%). Burn wound model of albino rats has been utilized for the assessment of wound healing potential of the plant extract as well as developed formulations. **Results and Conclusion:** The studies on burn wound healing model reveals that F2 poly-herbal ointment formulation show better burn wound healing potential in comparison to all other formulations, F-1 ointment formulation as well as extracts of all plants. There was no mortality observed in the tenure of study. **Discussion:** These data has indicated that ointment and gel poly-herbal formulation of *Nerium Indicum*, *Artocarpus Heterophyllus*, *Murraya Koenigii* and *Punica Granatum* has been utilized for wound healing purpose and it is safer for topical application. No toxicity and mortality has been observed during the experimental tenure.

Keywords: Wound healing, *Nerium indicum*, *Murraya koenigii*, *Punica granatum*, *Artocarpus heterophyllus*, burn wound model.

Article Info: Received 16 Jan 2019; Review Completed 12 Feb 2019; Accepted 13 Feb 2019; Available online 15 Feb 2019



Cite this article as:

Shukla R, Kashaw V, Extraction and wound healing potential of *Nerium Indicum M*, *Artocarpus Heterophyllus Lam*, *Murraya Koenigii L*, *Punica Granatum L* on albino rats using burn wound model, Journal of Drug Delivery and Therapeutics. 2019; 9(1-s):337-346 DOI: <http://dx.doi.org/10.22270/jddt.v9i1-s.2360>

*Address for Correspondence:

Dr. (Mrs.) Varsha Kashaw, Professor, SVN Institute of Pharmaceutical Sciences, Swami Vivekananda University, Sagar (M.P.) India

INTRODUCTION

Wound infection is one of the most common diseases in developing countries because of poor hygienic conditions¹. Wounds are the physical injuries that result in an opening or breaking of the skin and appropriate method for healing of wounds is essential for the restoration of disrupted anatomical continuity and disturbed functional status of the skin². Wound healing process holds several steps which involve coagulation, inflammation, formation of granulation tissue, matrix formation, remodeling of connective tissue, collagenization and aquisition of wound strength³⁻⁵.

***Nerium indicum Mill*:** *Nerium indicum mill*, also known as Kaner (Figure 1). It is evergreen shrub that grows up to 5m in height⁶. It is also used as antimalarial, anti-diuretic,

emetic, expectorant, cardiotonic, anticancer and applied in the treatment of cardiac asthma. Leaves and flowers are used to treat malaria and as traditional medicine it induces the termination of embryo. The root powder is an external remedy for hemorrhoids and ulcers around genitals. *Nerium indicum Mill* has gain many properties like bitter, acrid, astringent, anthelmintic, aphrodisiac, stomachic, febrifuge. The white flower variety plant *Nerium indicum mill* is exclusively native to india, Bangladesh, Nepal, Myanmar, and china. It is most commonly known as oleander, from its superficial resemblance to the unrelated olive *Olea*⁷.

It is also used as antidiabetic in Morocco⁸. In Philippines, the plant is used as ethno-medicine to treat fever, headache, and dermatological problems⁹. In Morocco, *N. indicum* is used in the treatment of hypertension and diabetes¹⁰.



Figure 1: Leaves of *Nerium Indicum Mill* (Kaner)

Artocarpus heterophyllus Lam: *Artocarpus heterophyllus Lam* (Figure 2) is a species of tree of the mulberry family Moraceae. It is also known as jackfruit (Eng.), Kathal (Hindi), Kanthal (Beng.). It is native to Western Ghats of India, Malaysia, central and eastern Africa and south-eastern Asia¹¹. The *Artocarpus heterophyllus Lam* contains various chemical

constituents as several flavones, colouring matters, morin, dihydromorin, cynomacurin, artocarpin, isoartocarpin, cyloartocarpin, artocarpesin, oxydihydro artocarpesin, artocarpetin, norartocarpetin, cycloartinone and artocarpanone¹².



Figure 2: Fruit of *Artocarpus heterophyllus Lam* (Jackfruit, Kathal)

Artocarpus heterophyllus Lam has utilized for fever, boils, wounds and skin diseases, astringent, and carminative, laxative, aphrodisiac, brain tonic, diuretic. The wood is nervine, anti-diabetic, antibacterial, sedative and useful in convulsions¹³. The wood has a sedative property and its pith is said to be abortifacient. Latex is used as an anti-inflammatory agent¹⁴.

The heart wood on analysis yields moisture 6.7%, glucosides 38.0%, lipids 0.7%, albumin 1.7% and cellulose 59.0¹⁵. The plant also contains free sugar (sucrose), fatty acids, ellagic acid and some essential Amino acids like Arginine, cystine, histidine, leucine, lysine, methionine, theanine, tryptophan¹⁶. The leaves and stem show the presence of sapogenins, cycloartenone, cycloartenol, β -sitosterol and

tannins, they show estrogenic activity. A root contains β -sitosterol, ursolic acid, betulinic acid and cycloartenone¹⁷.

Punica granatum Linn: *Punica granatum Linn* (Figure 3) is a deep-rooted but slow-growing, spiny, deciduous shrub or small multipurpose tree, it is particularly valued for its edible fruit, but also has medicinal properties, is a good source of tannins and has many agro-forestry applications. Fruit-raw, juicy and refreshing with a sub-acid flavor. The fruit is 5-13 cm in diameter; it has a hard, tough case that contains lots of seeds, each surrounded by a delicious juicy red flesh¹⁸. The fruit juice can be used in soups, sauces, jellies, ice cream, cakes etc. The fruit contains about 1.5% protein, 1.6% fat, 16.8% carbohydrate, 0.6% ash¹⁹.



Figure 3: Fruit of *Punica Granatum Linn* (Anardana)

All parts of the plant contain unusual alkaloids, known as 'pelletierines', which paralyse tapeworms so that they are easily expelled from the body by using a laxative. The plant is also rich in tannin, which makes it an effective astringent. It is used externally in the treatment of vaginal discharges, mouth sores and throat infections. The whole plant, but in particular the bark, is having antibacterial, antifungal²⁰, antiviral, anticancer²¹ and astringent properties. The flowers are used in the treatment of dysentery, stomach ache and cough. The juice of the flowers is used to treat nose bleeds. The seeds are demulcent and stomachic. It is also used as anti-diabetic²² and having antioxidant, anti-inflammatory²³, and anti-proliferation properties. A decoction of the seed is used to treat syphilis. The fruit is a mild astringent and refrigerant in some fevers and especially in biliousness. It is also cardiac and stomachic. The juice of the fruit is used to treat jaundice and diarrhea. It is a specific remedy for

tapeworm infestation. The rind of the fruit is ground in water and drunk every morning by diabetics.

***Murraya koenigii* Linn:** *Murraya koenigii* Linn, called curry leaf (Figure 4), is a small, tropical to sub-tropical tree or shrub that typically grows to 6-15' tall and is noted for its pungent, aromatic, curry leaves which are an important flavoring used in Indian/Asian cuisine. This tree is native to moist forests in India and Sri Lanka. Fragrant white flowers (each to 5/16" across) in many flowered panicles (terminal cymes) bloom irregularly throughout the year. They are best used fresh in cooking (dried leaves may be used but have significantly diminished flavor). Aroma/flavor of the fresh leaves is enhanced when the leaves are fried in oil or butte²⁴. Curry leaves are often added to vegetable dishes. They add subtle flavors to many other dishes, including meat, seafood, chutneys, coconut sauces, relishes, marinades and omelets.



Figure 4: Leaf of *Murraya koenigii* Linn (curry leaf)

It is a warming, strongly aromatic herb that improves appetite and digestion. The leaves, roots and bark can all be used internally in the treatment of digestive problems. The oil obtained from the leaves used as antioxidant, anthelmintic and antibacterial properties²⁵. It has been shown that the leaves increase digestive secretions; relieve nausea, indigestion and vomiting. The leaves can be used internally in treating constipation, colic, antimicrobial and diarrhea. The leaves are used in the treatment of diarrhea and dysentery. The leaves can be applied externally as a poultice to treat burns and wounds²⁶. The roots and bark are harvested as required and can be used fresh or dried. A paste made from the bark is applied to the bites of poisonous insects and other animals.

The objective of present work is to evaluate the wound healing potential of some Indian plant including *Nerium Indicum* Mill, *Artocarpus Heterophyllus* Lam, *Murraya Koenigii* Linn and *Punica Granatum* Linn using burn wound model. Two ointment (F1 & F2) and Gel (F3 & F4) formulations were prepared for topical application and compare with extract of individual plants.

MATERIALS AND METHOD

Plant material collection and authentication

The leaves of *Nerium Indicum* Mill (NI) were collected at in the month of June, 2016 from local area of Shubham Nursery Bhopal M.P., Pulp of *Artocarpus Heterophyllus* Lam (AH) and Whole plant of *Murraya Koenigii* Linn (MK) from local market of Barkheda and Bark of *Punica Granatum* Linn (PG) from Vidisha district, Madhya Pradesh. The specimens were submitted and identified as leaves of *Nerium indicum* Mill, pulp of *Artocarpus Heterophyllus* linn, bark of *Punica Granatum* Linn, Whole plant of *Murraya Koenigii* Linn and authenticated by Dr. Zia ul Hassan, Department of Botany,

Saifia Science College, Bhopal. The oppression no. for the specimen is 498/BS/saifia/NI_MK_PG_AH/04/16/07 has been preserved for future identification. The samples were shade dried so as to protect its chemical constituents not to get degrade at high temp.

Extraction

The leaves of NI, pulp of AH, bark of PG and leaves of MK were separated from the fresh and dried on filter paper sheets under shade at room temperature until with changing of color of filter papers. The shade-dried, coarsely powdered materials (500g) were defatted by petroleum ether (45°C). The defatted marc was then subjected to Soxhlet extraction with 70% ethanol to obtain hydro-alcoholic extract. The hydro-alcoholic extracts were evaporated under reduced pressure at low temperature (30°C) to dryness to yield different extracts, stored in an airtight container in refrigerator for further experimental studies.

Preparation of ointment and gel formulations

Poly-herbal formulation of all four plants has been prepared after completion of extraction and phyto-chemical studies. In this regards water soluble base is first choice for the formulation development of poly-herbal ointment and gel formulations. Water soluble base was used by their ease of preparation and cleaning after application.

Formulation of ointment:

Poly-herbal ointment formulation was prepared by the fusion method²⁷. Polyethylene glycol (PEG) Ointment base, a mixture of PEG 4000 and PEG 600²⁸ found to have sufficient consistency in ratio 3:7 respectively, thus suitable for ointment preparation with concentration of 10% & 15% (w/w) of all plants extracts. Two formulations F1 and F2 were prepared by Fusion method e.g. one containing all four

extracts of above mentioned plants parts in equal ratio i.e. 2.5% (w/w) of each extract for the preparation of 10 % (w/w) ointment in PEG ointment base (treated as poly-herbal-I or test-I) and the other one containing all four extracts of above mentioned plants parts in equal ratios i.e.

containing 3.75% (w/w) of each extract, equal to total 15% (w/w) in PEG ointment base (treated as poly-herbal-II or test-II). The prepared formulations was then evaluated by various parameters e.g. consistency, stability²⁹. The Quantity used for the ointment formulation was depicted in **Table-1**.

Table 1: Formulation of Ointment

S. No.	Content	Quantity (%)	
		F1	F2
1.	<i>Nerium indicum</i> Linn. (Leaves extract)	2.5	3.75
2.	<i>Murraya koenigii</i> (whole plant extract)	2.5	3.75
3.	<i>Punica granatum</i> (bark extract)	2.5	3.75
4.	<i>Artocarpus heterophyllus</i> (Pulp extract)	2.5	3.75
5.	Ointment base	Q.S.	Q.S.

Formulation of topical Gel:

Topical gel formulations of different concentration using carbopol base were formulated. The various ingredients used for the two different formulations are mentioned in

Table 2. All formulations were having carbopol gel base. Formulations I was 2.5% (w/w) of each extract for the preparation of 10% (w/w) gel and formulation II was 3.75% concentration of each extract for the preparation of 15% (w/w) gel, mixed properly with stirrer³⁰⁻³².

Table 2: Formulation of Topical Gel

S. No.	Content	Quantity (For 100 ml)	
		F3 (10%w/w)	F4 (15%w/w)
1	<i>Nerium indicum</i> Linn. (Leaves extract)	2.5	3.75
2	<i>Murraya koenigii</i> (Whole plant extract)	2.5	3.75
3	<i>Punica granatum</i> (Bark extract)	2.5	3.75
4	<i>Artocarpus heterophyllus</i> (Pulp extract)	2.5	3.75
5	Carbopol 940	1	1
6	Glycerin	5 ml	5 ml
7	Tri-ethanolamine	Q.S.	Q.S.
8	Propyl paraben	Q.S.	Q.S.
9	Distilled water	Q.S.	Q.S.

Pharmacological Activity

Wound healing activity

Selection of Model

Incision model, using Albino rats was selected for assessing the wound healing activity. These models were employed to study the rate of wound contraction, time required for full epithelization and tensile strength. These parameters were selected and albino rats were selected because of easy availability and simplicity in handling them.

Selection and procurement of animals:

Institutional animal ethics committee (IAEC) permitted for the animal studies (Reg. No.: CPCSEA/1413/PO/ES/07). Albino rats of either sex were procured and weighing 150-200 gm was selected. All were maintained at 24-28°C, housed individually with free access to food and water. They were fed with standard diet and kept in well-ventilated animal house with alternate dark-light cycle of 12h throughout the studies.

Oral toxicity studies

Albino rats of weight 150-200gm were selected for acute oral toxicity study and it was conducted according to the "Organization for Environmental Control Development" guidelines (OECD: Guidelines 420; Fixed Dose Method) for oral administration of extracts. Eighteen hour overnight fasted animals were subjected to oral administration of

extracts at a dose of 2000 mg/kg body weight. All the animals were kept under observation for first 3h for any changes or toxic effects like neurological, gross behavioral and lethality. The animals were observed and confirmed the absence of any toxic effects, hence two dose of combination 10% and 15% ointment were prepared with simple ointment and gel base for topical application and 10mg/ml oral dose taken for study.

Burn wound model

For the burn wound studies, ninety albino rats were taken divided in fifteen groups of six each. Rats depilated by removing hairs at the dorsal thoracic region before wounding. Rats were anaesthetized by diethyl ether prior to wound creation.

To perform the experiment, the rats were divided into fifteen groups (n=6).

Group I: Kept as Control group which received simple vehicle (PEG Ointment base)

Group II: Kept as Standard group received Povidone iodine

Group III: Kept as Test I which received Formulation F1

Group IV: Kept as Test II which received Formulation F2

Group V: Test group which received NIL5% extract topically

Group VI: Test group which received NIL10% extract topically

Group VII: Test group which received MKL 5% extract topically

Group VIII: Test group which received MKL 10% extract topically

Group IX: Test group which received PGB 5% extract topically

Group X: Test group which received PGB 10% extract topically

Group XI: Test group which received AHP 5% extract topically

Group XII: Test group which received AHP 10% extract topically

Group XIII: Test group which received Formulation F3 topically

Group XIV: Test group which received Formulation F4 topically

Group XV: Kept as Control group II which received simple vehicle (Gel base).

Creation of Burn Wound

Burn wounds were created on dorsal part of shaved rat's skin surface using concentrate sulfuric acid, exposed for 10 s. After 24 h, dead tissues were excised using sterile surgical blade through a template designed to produce a third degree burn. All groups were treated same as in excision model. In this model epithelialization period and tensile strength was monitored. A specimen sample from the healed wound of tissue was collected from each rat for histopathological examination³³⁻³⁴.

Hydroxyproline estimation

Wound tissues were analyzed for hydroxyproline content, a basic constituent of collagen. Tissues were dried in a hot air

oven at 60-70°C to constant weight and hydrolyzed in 6N HCl at 130°C for 4h in sealed tubes. The hydrolysate was neutralized to pH 7 and then subjected to chloramine-T oxidation for 20 min³⁵. These reactions was terminated by the addition of 0.4M perchloric acid and developed color with Ehrlich reagent at 60°C was read at 557 nm in ultraviolet spectrophotometer.

Histopathological Studies

The skin specimens were collected in 10% buffered formalin from rats of the twelve groups. Then, 5 µm thick sections were sliced and stained with haematoxylin and eosin. The light microscope was used to evaluate the sliced sections in terms of collagen formation, fibroblast proliferation, keratinisation, and epithelisation.

Statistical Analysis

Statistical analysis was performed using Graph-pad Prism version 7 for Windows (Graph-pad Software, San Diego, CA, USA) and Microsoft Excel 2013. Raw data obtained from different wound models are expressed as mean ± SEM. Values less than 0.05 were considered to be statistically significant. The data were analyzed using Graph-pad Prism version 7 for Windows and differences among groups were compared by one-way ANOVA followed by Dunnett's.

RESULTS AND DISCUSSION

Extraction

The extraction was done by continuous hot percolation method i.e. Soxhlet apparatus. The dried and pulverized drug was defatted with petroleum ether. The obtained marc was then extracted with 70% Hydro-alcoholic solution. The drying of extract containing solvent (70% hydro alcoholic solution) was done by rota vacuum evaporator. The data depicted in the Table 3.

Table 3: Percentage yield of hydro-alcoholic extracts from different drugs

S. No.	Parts	Extract color	Yield (in gm)	% Yield (w/w)
1.	NIL	Greenish brown	20.43	26.28
2.	AHP	Yellowish	8.24	10.05
3.	PGB	Dark brown	8.97	11.34
4.	MKL	Greenish brown	20.76	26.11

Initially 80 g of crude drug was taken. **Where NIL-** Hydroalcoholic Extract of *Neium indicum* leaves, **AHP-**Hydroalcoholic Extract of *Artrocarpus heterophyllus* pulp, **PGB-** Hydroalcoholic Extract of *Punica granatum* Linn.Barkand **MKL-** Hydroalcoholic Extract of *Murraya Koenigi* Linn.whole plant.

Burn Wound Model

Burn Model

In the biochemical analysis, it was observed that hydroxyproline content was increased in the F1- F4 extract formulation treated animals, which in turn is a reflection of

increased cellular proliferation and increased collagen synthesis (Table 5). The synthesized collagen confers integrity, strength of the tissue matrix and also helps in maintaining homeostasis and epithelialisation at the later phase of healing, thus remodelling of a new extracellular matrix produced.

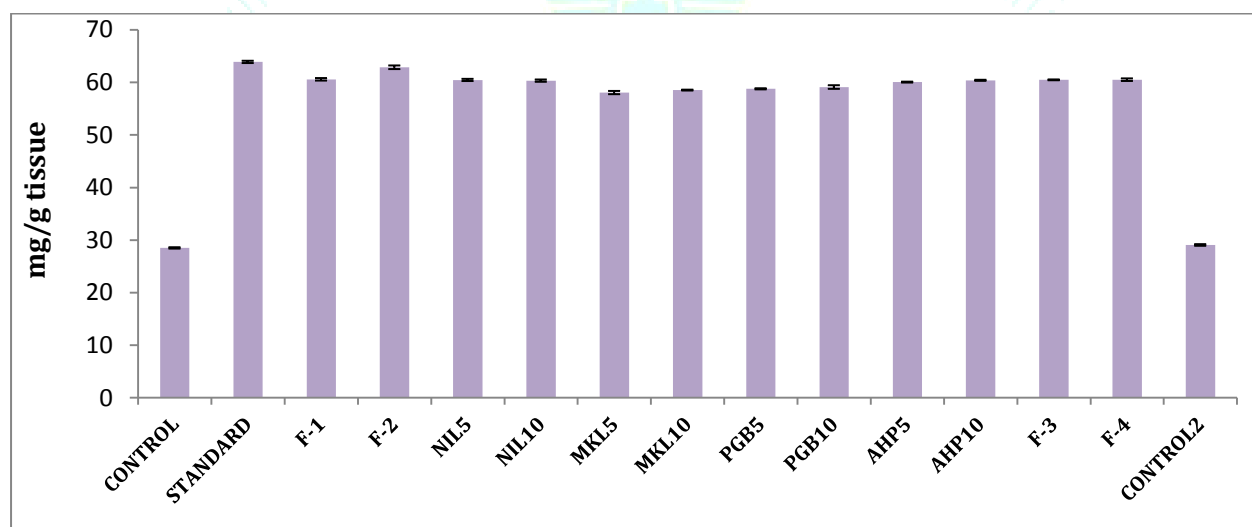Table 5: Effect of Various samples on Hydroxyproline Content (mg/g tissue) in Burn Wound Model

Group No.	Groups	Hydroxyproline Content(mg/g tissue)
I	CONTROL	28.51±0.128
II	STANDARD	63.89±0.216**
III	F-1	60.58±0.238*
IV	F-2	62.87±0.343**
V	NIL5	60.46±0.206*
VI	NIL10	60.33±0.216*
VII	MKL5	58.06±0.307
VIII	MKL10	58.53±0.079
IX	PGB5	58.77±0.103
X	PGB10	59.11±0.342
XI	AHP5	60.05±0.085*
XII	AHP10	60.39±0.098*
XIII	F-3	60.48±0.076*
XIV	F-4	60.51±0.243*
XV	CONTROL2	29.07±0.155

Note: n =6 animals in each group, values are expressed as Mean ±SEM, If * =p<0.05, ** =p<0.01, *** =p<0.001 when compare to control.

In the formulations [higher concentrations of extract containing formulations (e.g. 15% containing formulations)] treated burn injuries, improved epithelialization, wound contraction and granulation tissue formation was observed when compared to control indicating a rapid and important rise in hydroxyproline content. The hydroxyproline content was found in following order: Control < MKL5 < MKL10 < PGB5 < PGB10 < AHP5 < NIL10 < AHP10 < NIL5 < F3 < F4 < F1 < F2 < Standard. (Table 3) In the formulation treated

groups (F1, F2, F3 and F4), collagen mass reduced slowly during the last days of the treatment indicating the restructuring phase and on a contrary gradual rise in control groups till the last day indicating that it was still in the propagative stage. The absolute content of the indicator was corresponding to that in the control cohort. Effect of Various samples on Hydroxyproline Content (mg/g tissue) in Burn Wound Model was shown in Figure 5.

**Figure 5: Effect of Various samples on Hydroxyproline Content (mg/g tissue) in Burn Wound Model**

The process of wound healing involves migration of fibroblasts from the edges of wound to the site of wound, proliferate and generate collagen, which is the important component in the extracellular matrix. So, stimulation of the fibroblast and migration of keratinocytes, as confirmed in this study, might have been contributed to the wound healing process. The process of the wound healing pattern in the treated group was mainly because of the phytoconstituents present in the extract that might have the capacity to encourage the initial expression of growth factors or growth factor-like activity³⁶. The faster wound contraction by the blend formulation may be due to the stimulation of cytokine, an inflammatory α -chemokine by flavanoids, terpenes and gallic acid³⁷. Phytochemical constituents of the

herbal extract henna contain monoterpenoides, which have anti-inflammatory and antimicrobial properties³⁸⁻³⁹. The results of the wound healing activity of extract formulations by burn model method are represented in **Table 6 and Figure 6**. The results were expressed as tensile strength of burn wound area. The data revealed that skin breaking strength of control animals were decreased to significant extent in comparison to the formulation groups of *albino* albino rats ($p<0.01$ and $p<0.001$). The studies on burn wound healing model reveal that the formulation groups (F1, F2, F3 and F4) showed high breaking strength in wound area from 1st day to 10th day e.g. 507.08±5.98, 536.39±2.82, 500.16±3.43 and 503.77±2.58g/mm².

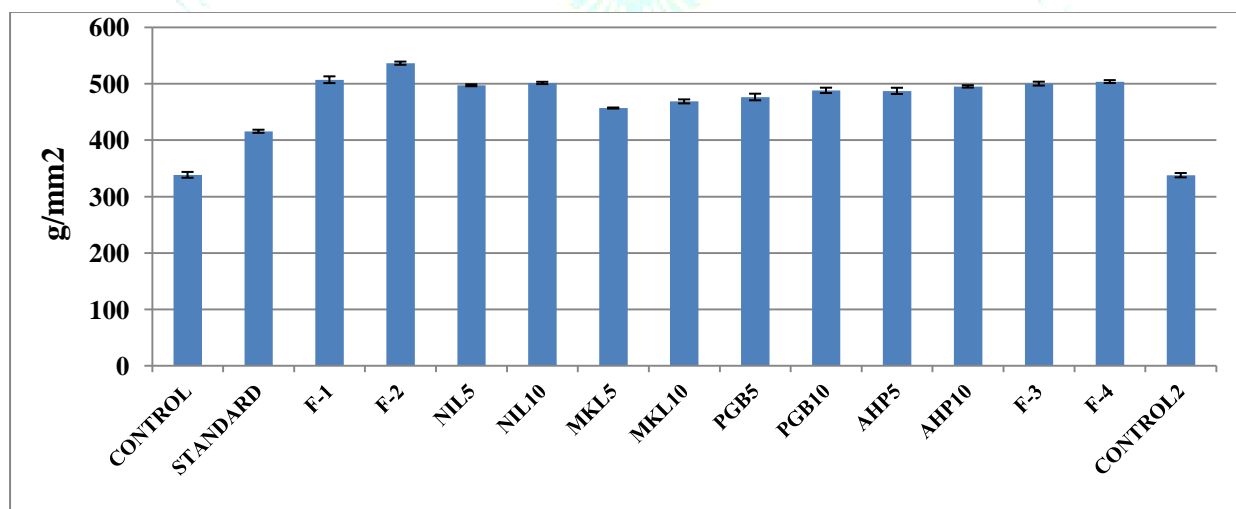
Table 6: Effect of Various samples on Tensile Strength (g/mm²) in Burn Wound Model

Group No.	Groups	Tensile Strength (g/mm ²) 10th day
I	CONTROL	338.49±5.15
II	STANDARD	415.71±2.74
III	F-1	507.08±5.98***
IV	F-2	536.39±2.82***
V	NIL5	497.22±1.71**
VI	NIL10	501.36±2.03**
VII	MKL5	456.89±0.91*
VIII	MKL10	468.64±3.54*
IX	PGB5	476.45±5.85*
X	PGB10	488.19±4.74**
XI	AHP5	487.26±5.53**
XII	AHP10	495.21±2.08**
XIII	F-3	500.16±3.43***
XIV	F-4	503.77±2.58***
XV	CONTROL2	337.87±3.84

Note: n =6 animals in each group, values are expressed as Mean ±SEM, If * =p<0.05, ** =p<0.01, *** =p<0.001 when compare to control.

The other test groups of individual drug formulations at different concentrations has shown different tensile strength results e.g. NIL5 and NIL10 shown 497.22±1.71 and 501.36±2.03, MKL5 and MKL10 shown 456.89±0.91 and 468.64±3.54, PGB5 and PGB10 shown 476.45±5.85 and 488.19±4.74, AHP5 and AHP10 shown 487.26±5.53 and 495.21±2.08 and F-3 and F-4 shown 500.16±3.43 and 503.77±2.58 respectively. Ointment formulations F-1, F-2, F-3 and F-4 have shown significant wound healing activity, which was comparable to that of standard marketed preparation. The F-2 formulation was found more active

than the F-1, F-3 and F-4. The tensile strength is more when compared to standard. On 10th day complete healing of wound was observed with standard marketed ointment, and ointment of formulations produced 507.08±5.98 (F-1) and 536.39±2.82 (F-2), 500.16±3.43 (F-3) and 503.77±2.58 (F-4) healing of wound as compared to control. The control (ointment base) has shown 338.49±5.15g/mm² healing. The healing time in the burn model in formulation groups was shorter than in the burn control group (25.54±0.152 days) and standard group (14.25±0.232 days) (Figure 7)

**Figure 6: Effect of Various Samples on Tensile Strength (g/mm²) in Burn Wound Model**

It was observed from this work that hydro-alcoholic extracts of individual drugs when used in combination formulations promotes the treatment of injuries caused by excision, incision and burn. The outcome was further supported by injury treatment trial in a rat model, *in vitro* experiments, and biochemical analysis of wound biopsy. The probable mechanism by which the extract acts and heals burn as well as other wounds may be by decreasing inflammatory response, increasing the flow of blood at the site and by reducing infection. The chemical constituents present in the NIL, AHP, MKL and PGB alkaloids, flavanoids, phenolic compounds, proteins, amino acids, glycosides and vitamins

may promote healing by induction of antioxidant enzymes and scavenging of free radicals. The higher total phenolic and flavanoids content supports its greater antioxidant potential. It was also observed that the early closure of wounds and reduction of complications may be attributed to the presence of some chemical constituents present in the hydro-alcoholic extract of the herbal drug formulations.

Phytochemical studies showed the presence of flavanoids and phenolic compounds in considerable amount supporting the activities of the selected medicinal plants. Optical photographs were taken from the wound area at 4, 8, 12 and 16 days (Figure 7).

Photographs of Animals Skin

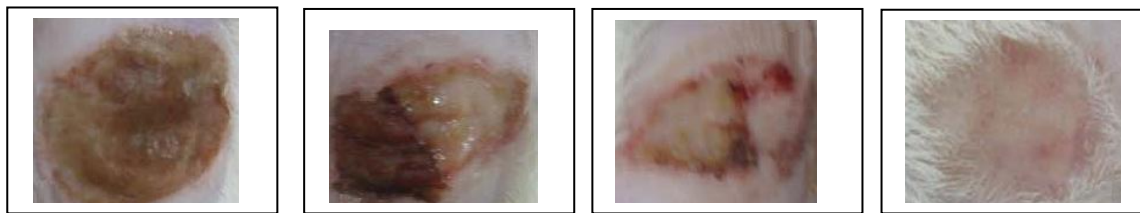


Figure 7: Healing activity of Best Group (F-2) in Burn wound

Epithelialization period:

In the first four days, there were brown scabs appearing in the burn wounds, which were not measurable different among the groups. There was significant improvement in the wound closure in formulation groups (F1, F2, F3 and F4) (Table 5), comparing to the burn control group, other individual drug formulations and standard group (Figure 8). The mean epithelialisation time in the burn wound model decreased from 25.54 days in controls, to 18.70 days for F1, 16.79 days for F-2, 19.79 days for NIL5, 18.83 days for NIL10, 22.25 days for MKL5, 22.12 days for MKL10, 21.29

days for PGB5, 20.75 days for PGB10, 20.62 days for AHP5, 19.12 days for AHP10, 18.85 days for F-3 and 18.98 days for F-4, while standard povidone iodine showed the lowest time of 14.25 days. The overall epithelialisation time can be presented as: Control > MKL5 > MKL10 > PGB5 > PGB10 > AHP5 > NIL5 > AHP10 > F-4 > F3 > NIL10 > F1 > F2 > Standard. Among the prepared herbal formulations, the blended formulations showed decrease in epithelisation period in comparison with controls, individual extracts and showed comparable results to the standard ointment (Table 7 and Figure 8).

Table 7: Effect of Various samples on Epithelialization period (mean time in days) in Burn Wound Model

Group No.	Groups	Epithelialization period (mean time in days)
I	CONTROL	25.54±0.152
II	STANDARD	14.25±0.232***
III	F-1	18.7±0.208**
IV	F-2	16.79±0.313**
V	NIL5	19.79±0.211**
VI	NIL10	18.83±0.142**
VII	MKL5	22.25±0.215
VIII	MKL10	22.12±0.227
IX	PGB5	21.29±0.146
X	PGB10	20.75±0.112*
XI	AHP5	20.62±0.103*
XII	AHP10	19.12±0.124**
XIII	F-3	18.85±0.174**
XIV	F-4	18.98±0.192**
XV	CONTROL2	25.43±0.149

Note: n =6 animals in each group, values are expressed as Mean ±SEM, If * $p < 0.05$, ** $p < 0.01$, *** $p < 0.001$ when compare to control.

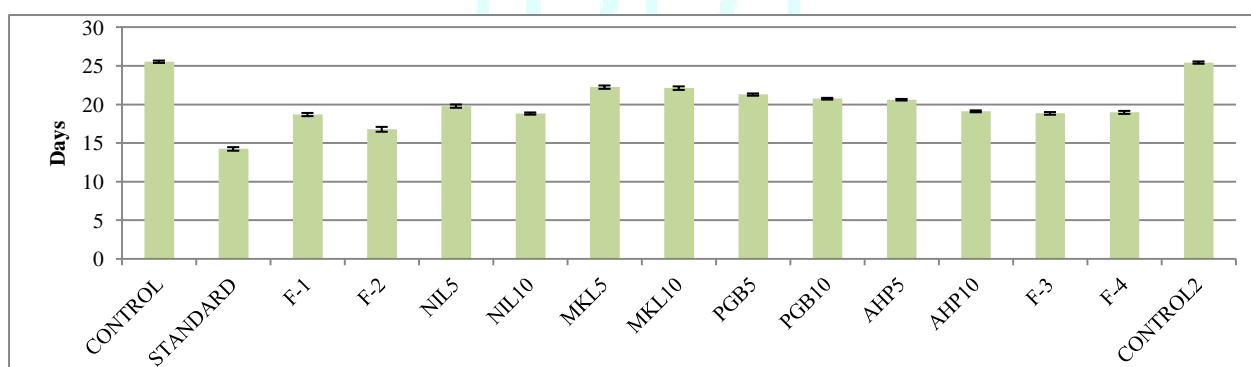


Figure 8: Effect of Various Samples on Epithelialization period (mean time in days) in Burn Wound Model

Histopathological evaluation

Histopathological evaluations showed the burn healing to be better in the (GIII, GIV, GXIV, GXIII, GV to GXII) with respect to the control group (Figure 9a-9o). In the untreated groups scab formations by the necrotic tissue remnants with mononuclear cell infiltration was observed. The various groups have regeneration and repairing in the epidermal layer. It was also observed that the inflammatory cell infiltration without an epithelial layer was present. In dermis the vessels were hyperaemic and there were no hair follicles,

sebaceous or sweat glands in the groups. The scab was thinner in the F2< F1< F3< F4 (GXIII< GXIV< GIII< GIV) group. It was noticed that during the regeneration and repairing there was an improvement in epithelial layer formation. At the subcutaneous level dermal fibrosis was observed. The epithelial layer in the Group XIII, Group XIV, Group III and Group IV had a better appearance when compared to control, standard and other groups. Those groups also have better granulation tissues situated in the dermis comparatively with the other groups.

Histopathological Changes (Burn)

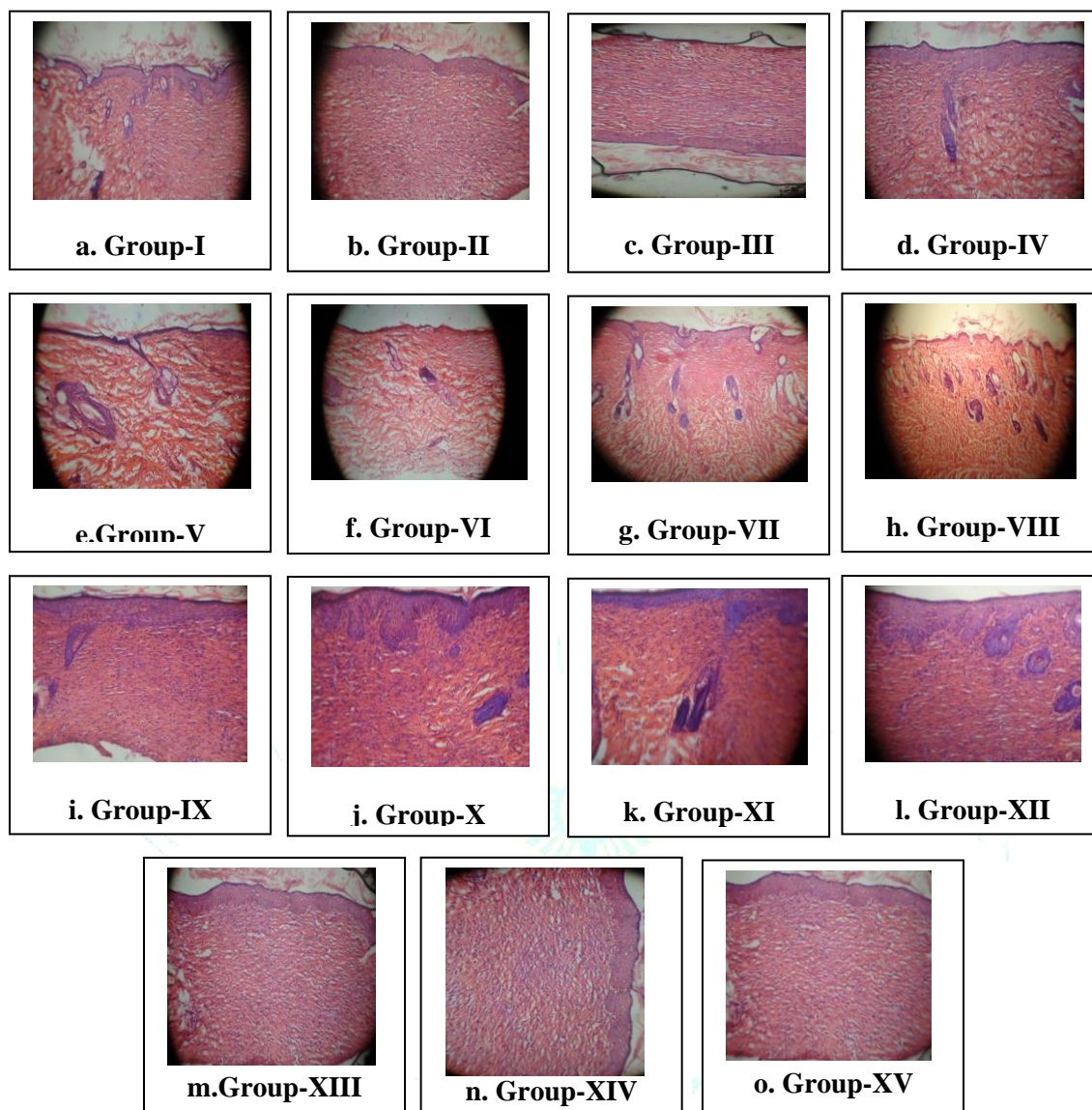


Figure 9: Histopathology of skin at day 10 stained with H&E (100X)

CONCLUSION

Incision wound model suggested that the four individual plant extract have shown the wound healing potential although the prepared ointment and gel formulations have better and synergistic action than individual. The ointment formulations were more effective than gel formulations and especially the formulation F2 has more wound healing potential among others. The poly-herbal formulations containing plant extracts in 15% amount has better wound healing potential.

SUMMARY

In the present research work ointment and gel formulations with extract of four herbal drugs was prepared and evaluated for the wound healing activity by Incision wound model in animals (albino rat). The hydro-alcoholic extracts prepared by using soxhletion method were incorporated in the ointment base for formulation. After completion of formulation they were evaluated for its physicochemical parameters like colour, odour, pH, spreadability, extrudability, consistency, diffusion study, solubility, washability. Also the formulations were evaluated for its stability at various temperature conditions which shows no change in the irritancy, spreadability and

diffusion study. The four individual drugs extracts e.g. *Nerium indicum* leaves, *Murraya koenigii* whole plant, *Punica granatum* bark and *Artocarpus heterophyllus* pulp has shown wound healing properties but the formulation F2 has shown better and improved results in wound healing. Thus it could become a medium to use the medicinal properties of extracts effectively and easily as a simple dosage form. The topical use of herbal ointment formulation accelerates the re-epithelialization of burn wound with proper healing process as compared with the marketed product. The experiment confirmed the therapeutic action of the NIL, PGB, AHP and MKL extracts and was supported by the *in vivo* data. The results obtained also provide rational pharmacological evidence for the use of the NIL, PGB, AHP and MKL extract in the treatment of various types of wounds. Results from this study deliver reasonable pharmacological proof for the use of herbal ointment formulation (F2) for the treatment of wounds. All the results indicated the effectiveness of herbal ointment F2 in enhancing wound healing activities. The herbal ointment prepared from hydralcoholic extract of *Nerium indicum* leaves, *Murraya koenigii* whole plant, *Punica granatum* bark and *Artocarpus heterophyllus* pulp showed marked reduction in wound area in comparison to control group when examined

for wound healing activity by topical application in albino rats. The formulation will be helpful in wound healing with no side effects and will be beneficial for society and industry with standardization approaches.

Conflicts of interest

The author declares no conflicts of interest.

REFERENCES

- Kumar S, Sripriya R, Raghavan VH. Wound healing potential of Cassia fistula on infected albino rat model, Journal of Surgical Research 2006; 23:283-89.
- Rashmi Shukla, Varsha Kashaw. Wound healing prospective of Pongamia glabra, Piper nigrum and Momordica charantia on albino rats using anemic burn wound model. Journal of Drug Delivery & Therapeutics. 2018; 8(6-s):146-154.
- Enoch S, John LD. Basic Science of wound healing. Ethnopharmacology. 2005; 23:37-42.
- Guo S, Dipietro LA. Factors affecting wound healing. Journal of Dental Research. 2010 89(3):219-229.
- Rashmi Shukla, Varsha Kashaw. Evaluation of wound healing prospective of Momordica charantia, Pongamia glabra and on anemic albino rats using incision wound model Piper nigrum. Asian Journal of Pharmacy and Pharmacology. 2019; 5(2):401-408.
- Nagargoje AN, Phad SS. A Review on phytochemistry and pharmacology of Nerium indicum Mill. Plant. International Journal of Pharmaceutical Sciences Review. 2003; 21(2):148-151.
- Dey P, Chaudhuri TK. Pharmacological aspects of Nerium indicum Mill, A comprehensive review. Pharmacognosy Review 2014; 8(16):156-162.
- Bnouham M, Mekhfi H, Legssyer A, Ziyat A. Medicinal plants used in the treatment of diabetes in Morocco. Int J Diabetes Metab. 2002; 10:33-50.
- Tantiado RG. Survey on ethnopharmacology of medicinal plants in Iloilo, Philippines. Int J Biosci Biotechnol. 2012; 4:11-26.
- Tahraoui A, El-Hilaly J, Israili ZH, Lyoussi B. Ethnopharmacological survey of plants used in the traditional treatment of hypertension and diabetes in south-eastern Morocco (Errachidia province). J Ethnopharmacol. 2007; 110:105-17. [PubMed: 17052873]
- Elevitch CE, Manner HI. Artocarpus heterophyllus (jackfruit). Species Profiles for Pacific Island Agroforestry 2006; 10: 1-25.
- Akhilhari H, Revikumar KG, Divya D. Artocarpus. A Review of its Phyto-chemistry and Pharmacology. Journal of Pharma Search. 2014; 9(1):7-13.
- Mohammed HPM, Rashid K, Senthil CK. Artocarpus Heterophyllus- review study on Potential Activity. Journal of Tropical Biology and Conservation. 2018; 15: 61-80.
- Burci LM, Silva CB, Rondon JN, Silva LM, Sergio FA, Miguel OG, Dias JFG, Miguel MD. Acute and subacute (28 days) toxicity, hemolytic and cytotoxic effect of Artocarpus heterophyllus seed extracts. 2018. Toxicology Reports. <https://doi.org/10.1016/j.toxrep.2018.02.006>.
- Baliga MS, Shivshankara AR, Haniadka R, Dsouza J, Bhat HP. Phytochemistry, nutritional and pharmacological properties of Artocarpus heterophyllus Lam (jackfruit). A review. Food Research International. 2011; 44 (7):1800-1811.
- Abu Bakar MF, Abdul Karim F, Perisamy E. Comparison of phytochemicals and antioxidant properties of different fruit parts of selected Artocarpus species from Sabah, Malaysia. Sains Malays. 2015; 44(3):355-363.
- Ojwang RA, Muge EK, Mbatia BN, Mwanza BK, Ogoyi DO. Compositional, elemental, phytochemical and antioxidant characterization of Jackfruit (Artocarpus heterophyllus) Pulp and Seeds from Selected Regions in Kenya and Uganda. European Journal of Medical physics. 2018; 23(3):1-12.
- Shirote PJ, Deepali SS, Thorat SS. Isolation, phytochemical screening and biological evaluation of Punica granatum leaves extract. European Journal of Pharmaceutical and Medical Research. 2018; 5(7):271-275.
- Sangeetha R, Jayaprakash A. Phytochemical Screening of Punica granatum Linn. Peel Extracts. Journal of Academic and Industrial Research. 2015; 4:160-162.
- Mansourian A, Boojarpour N, Ashnagar S, Bejtollahi JM, Shamshiri AR. The comparative study of antifungal activity of Syzygium aromaticum, Punica granatum and nystatin on Candida albicans-an *in-vitro* study. 2014; 24(4):163-168.
- Li Y, Yang F, Zheng W. Punica granatum (pomegranate) leaves extract induces apoptosis through mitochondrial intrinsic pathway and inhibits migration and invasion in nonsmall cell lung cancer in vitro. Biomed Pharmacother. 2016; 80:227-35.
- Ali Redha AA, Hasan AM, Mandeel Q. Phytochemical Determinations of Pomegranate (Punica granatum) Rind and Aril Extracts and their Antioxidant, Antidiabetic and Antibacterial Activity. Nat Prod Chem Res. 2018; 64:15-20.
- Amer OSO, Dkhil MA, Hikal WM, Al Quraishy S. Antioxidant and Anti-Inflammatory Activities of Pomegranate (Punica granatum) on Eimeria papillata-Induced Infection in Mice. Bio Med Research International. 2015; 2015:219670.
- Singh S, More PK, Mohan SM. Curry leaves (Murraya koenigii Linn. Sprengal)-a miracle plant. Indian Journal of Scientific Research. 2014; 4:46-52.
- Rajendran MP, Pallaiyan BB, Selvaraj N. Chemical composition, antibacterial and antioxidant profile of essential oil from Murraya koenigii (L.) leaves. Avicenna J Phytomed. 2014; 4(3):200-214.
- Jadhav VS, Ghawate VB. Evaluation of combined wound healing activity of ethanolic extracts of leaves of Murraya koenigii and Nyctanthes arbortristis on rats. Drug Invention Today. 2017; 9(2): 24-27.
- Shubhangi ES, Monali DT. Formulation and evaluation of herbal ointment containing Neem and Turmeric extract. Journal of Scientific and Innovative Research. 2016; 5(4):149-151.
- Asija R, Dhaker PC, Nema N. Formulation & evaluation of voriconazole ointment for topical delivery. Journal of Drug Discovery and Therapeutics. 2015; 26(3):7-14.
- Sawant SE, Tajane MD. Formulation and evaluation of herbal ointment containing Neem and Turmeric extract. Journal of Scientific and Innovative Research. 2016; 5(4):149-151.
- Mishra NN, Kesharwani A, Agarwal A, Polachira SK, Nair R, Gupta SK. Herbal Gel Formulation Developed for Anti-Human Immunodeficiency Virus (HIV)-1 Activity Also Inhibits In-vitro HSV-2 Infection. Viruses. 2018; 2410(11):E580. doi: 10.3390/v10110580.
- Shahtalebi MA, Asghari GR, Rahmani F, Shafiee F, Jahanian-Najafabadi A. Formulation of Herbal Gel of Antirrhinum majus Extract and Evaluation of its Anti-Propionibacterium acne Effects. Adv Biomed Res. 2018; 7:53. doi: 10.4103/abr.abr_9_17. eCollection 2018.
- Aslani, A., Zolfaghari, B., & Fereidani, Y. Design, formulation, and evaluation of a herbal gel contains melissa, sumac, licorice, rosemary, and geranium for treatment of recurrent labial herpes infections. Dental Research Journal. 2018; 15(3):191-200.
- Nakae H, Inaba H. Effectiveness of electrolyzed oxidized water irrigation in a burn-wound infection model. J Trauma. 2000; 49:511-514.
- Pawar RSP, Chourasiya PK, Rajak H, Singour PK, Toppo FA, Jain A. Wound healing activity of Sida cordifolia Linn. in rats, 2013; 45(5): 474-478.
- Woessner JF, Jr The determination of hydroxyproline in tissue and protein samples containing small proportions of this imino acid. Arch Biochem Biophys. 1961; 93:440-447.
- Gnanamani A, Priya KS, Radhakrishnan N, Babu M. Antibacterial activity of two plant ex-tracts on eight burn pathogens. J Ethnopharmacol. 2003; 86: 59-61.
- Moyer KE, Saggars GC, Allison GM, Mackay DR. Ehrlich HP. Effects of interleukin-8 on granulation tissue maturation, J. Cell. Physiol. 2002; 193(2):173-179.
- Chmit M, Kanaan H, Habib J, Abbass M, McHeik A, Chokr A. Antibacterial and antibiofilm activities of polysaccharides, essential oil, and fatty oil extracted from Laurus nobilis growing in Lebanon. Asian Pac. J. Trop. Med. 2014; 7S1: S546-S552.
- Tabanca N, Avonto C, Wang M, Parcher A. Ali, Demirci B, Raman V, Khan IA. Comparative investigation of Umbellularia californica and Laurus nobilis leaf essential oils and identification of constituents active against Aedes aegypti. Journal of Agriculture Food Chemistry. 2013; 61(50):12283-12291.