

Available online on 15.12.2018 at <http://jddtonline.info>

Journal of Drug Delivery and Therapeutics

Open Access to Pharmaceutical and Medical Research

© 2011-18, publisher and licensee JDDT, This is an Open Access article which permits unrestricted non-commercial use, provided the original work is properly cited

Open  Access

Research Article

A novel approach for failed lumbar spine surgery with topical phytotherapeutic treatment: a unique case study

Ganguly Apurba* and Ganguly Devika

Department of Research and Development, OPTM Research Institute, India

ABSTRACT

Objective: The aim of the study was to treat successfully the failed Lumbar Spinal Fusion Surgery (LSFS) with topical phytotherapy within twelve-week.

Methods: A male patient, aged 45years, was cripple with acute pain due to slipped disc for 4years and subsequently undergone LSFS at L₄-L₅ 3years back. Being failed in surgery, he was treated with topical application of phytoextracts of seven medicinal plants (*Cissus quadrangularis*, *Calotropis gigantea*, *Zingiber officinalis*, *Rosemarinus officinalis*, *Boswellia serrata*, *Curcuma longa* and *Withania somnifera*) mixed with sesame oil and beeswax with specialized technique for twelve-week.

Results: The percentages of improvements in international-approved pain related abnormalities and overweight were observed after post-treatment: Visual Analogue Scale (VAS) (Right leg: 94.91, Left leg: 94.87 and Lower back: 93.62), WOMAC index (Pain: 88.23, Stiffness: 84.71 and Physical function: 74.07), Oswestry Disability index (ODI) (74.47), Lower Extremity Functional Scale (LEFS) (62.50), Karnofsky Performance Scale (KPS) (80.00) and Body Mass Index (BMI) (11.93) and substantial improvement in radiological images as assessed by KL grading scale (≥ 2).

Conclusion: Results showed the failed LSFS at L₄-L₅ can be successfully treated with specialized topical phytotherapy within twelve-week, evidenced by normalization of international acclaimed pain parameters such as VAS, WOMAC index, ODI, LEFS, KPS and BMI and radiological feature as assessed by KL grading scale.

Key word: Intervertebral disc degeneration; Failed spine surgery; Phytoextracts; Phytotherapy for failed LSFS; Medicinal plants



Article Info: Received 27 Oct 2018; Review Completed 01 Dec 2018; Accepted 03 Dec 2018; Available online 15 Dec 2018

Cite this article as:

Ganguly A, Ganguly D, A novel approach for failed lumbar spine surgery with topical phytotherapeutic treatment: a unique case study, *Journal of Drug Delivery and Therapeutics*. 2018; 8(6-s):135-140

DOI: <http://dx.doi.org/10.22270/jddt.v8i6-s.2214>

*Address for Correspondence:

Apurba Ganguly, Founder and Chief Scientist, OPTM Research Institute, 145 Rashbehari Avenue, Kolkata - 700029, India,

INTRODUCTION

Lumbar slipped disc (LSD) is a chronic painful condition in which nucleus pulposus (jelly like substance) of intervertebral disc, mostly L₄ - L₅ or L₅ - S₁, protrudes through the fibrous tough outer-wall (annulus fibrosus) of the disc resulting which put the pressure on the nearby nerve root causes inflammation, irritations, pain radiating to buttocks, thighs, calves, feet and arms, numbness, weakness in the lower limbs, or paralysis, or loss of control of bowel and bladder or sexual dysfunction, thus to lead to abnormal quality of life.¹⁻¹⁰ The author has already

investigated the various risk factors and phytotherapeutic treatment protocol for LSD/ Herniated disc in the previous studies.¹¹⁻¹² When all the treatments such as medications including corticosteroid injections and physical therapies failed, among many surgical procedures the spinal fusion surgery is the ultimate treatment for LSD.¹² But, when the surgery is under taken at the vertebral levels L₄ - L₅ or L₅ - S₁, other vertebrae of the lower spine are compressed in the long run (Figure 10A) causes inflammation, pain, numbness and weakness of lower limbs and finally become crippled as before.¹³

Table 1. Demographic data and baseline characteristics	
Parameter	Patient
Age (years)	48
Gender	Male
Period of suffering (years)	7
Surgery done at the age	45
Weight (kg)	87.94
Height (m)	1.64
BMI (kg/m ²)	32.69
Indian ethnic group	Bengali
Dietary habit	Non-vegetarian
Other habits	Smoking, alcohol
Work status	Self employed
Marital status	Married
Grade in KL grading scale	≥ 4
Multiple complaints	
Constipation	Present
Acidity and reflux	Not present
Insomnia	Present
Varicose vein	Not Present
Urinary incontinence	Present
Psychosomatic disorders	Anxiety, Depression
Pain on knee joints	Present (bilateral)
Crepitus during knee flexion	Present
Morning stiffness (<30min)	Present
Measures taken to diminished pain & Inflammation	
Knee-cap used (right or left)	Left
Belt used	Lumbar
Paracetamol/NSAIDs	NSAIDs
Corticosteroid injection	6 times previously
Walking support	Walker
Physiotherapy done (years)	3
Undergoing alternative treatment	Ayurvedic & Homeopathic
Supplements for pain or fitness	Calcium & Vitamin D

Table 2 Baseline Characteristics of pain parameters	
Parameter	Baseline
Under VAS (mm):	
Right leg	59
Left leg	78
Lower back	94
Under WOMAC index (%)	
Pain	85.00
Stiffness	87.50
Physical function	83.82
OVERALL	84.35
Under ODI (%)	
Pain intensity	100
Personal care	100

Lifting	100
Walking	80
Sitting	80
Standing	100
Sleeping	80
Sex life	100
Social life	100
Travelling	100
TOTAL	94
Under LEFS (%)	10
Under KPS (%)	50

CASE STUDY

A male patient aged 45 years old was undergone lumbar spinal fusion surgery at L₄-L₅ three years back as he was suffering with severe pain and weakness radiating to lower limbs, numbness and unable to performed daily activities for the last four years. After the surgery, the man has again become crippled as before after three years and advice for revision LSFS. Being unsuccessful in surgery, he came to OPTM Healthcare (P) Ltd., India, for treatment during the month of January 2018. The study protocol was evaluated and approved by the OPTM Research Institute Ethics Committee. An institutional review board-approved consent form for physical examinations and bilateral knee-joint and lumbosacral spine images (X-rays) required for the study was signed by the patient. Baseline demographic characteristics and pain parameters of the patient are shown in Tables 1-2. The said patient was not being treated by oral medications; injections; massage with any type of herbal gels; and any type of alternative interventions or treatments for diminishing pain or inflammation, for muscle relaxation, or to improve of the skeletal muscles during the last four weeks prior to the treatment of 12 weeks. The radiological features were observed bone erosion and compression between all the lumbar vertebrae and required revision surgical intervention as the patient was suffering with severe pain, stiffness and physical functional disabilities (Tables 2). The radiological images (before and after the treatment) is depicted in Figure 10.

The main objectives of the treatment are: to reduce pain, inflammation and stiffness of muscles without dependence upon any types of pain killers or corticosteroid injection or surgical intervention; to increase the muscular strength without using supporting belt on the waist; to reduce the compression between the vertebrae without lumbar disk arthroplasty (Figures 1-10).¹⁴⁻¹⁵

The treatment involves topical application of phytoconstituents from the extracts of seven Indian medicinal plants namely *Cissus quadrangularis* (whole plant), *Zingiber officinalis* (rhizome), *Rosemarinus officinalis* (leaves and flowers), *Calotropis gigantea* (root and leaves), *Withania somnifera* (root) *Boswellia serrata* (resin) and *Curcuma longa* (rhizome) mixed with virgin sesame oil (extracted from seeds at room temperature) and beeswax to make viscous phyto-based oil without using any preservatives or chemicals in order to preserve the phytochemical properties of plants intact. The virgin sesame oil is acted as bio-preservative and beeswax helps to reduce joint pain, to relieve stiffness, to stimulate circulation and to moisturize skin.¹⁴⁻²⁷ Several researchers had already reported the medicinal effects on pain,

inflammation and stiffness of muscles on human body of the phytochemicals contained in above mentioned plants.¹⁴⁻²⁷

Each 30 ml of said viscous phyto-based oil is to be applied with the tip of three fingers in particular technique over the skin three times a day with minimum interval of two hours for 12 weeks; lying in six different postural positions such as supine, prone, right and left contralateral and right and left cross contralateral in different programmed sequences in order to nourish the effected group of badly damaged muscles and nerves in the legs and lumbar region during LSD.¹⁴⁻¹⁶ The author had previously discussed elaborately, the reasons of the programmed sequences with six postural positions, and the purpose of special devices such as medicated pad, wooden roller and battery-operated electronic nerve stimulator used during the therapy.^{14-16, 26}

The treatment protocol is based on well-defined certain principles and theories and based on the fundamental properties of all muscles such as excitability, conductivity, contractibility, elasticity and viscosity with the help of well-known chemical, mechanical, thermal and electrical stimuli.¹⁴⁻¹⁶ In the phytotherapy protocol, viscous phyto-based oil serves the purpose of producing chemical stimulation, manipulation with the tip of three fingers and wooden roller develop mechanical stimulation, medicated pads with control temperature generates thermal stimulation and 9-volt DC electronic nerve stimulator produces electrical stimulation.^{14-16, 26} Table 2 summarizes the pain and performance parameters of the patient at pre-treatment. The patient underwent X-ray examination of the lower back, wherein large osteophytes with compressions between all the vertebrae were observed (Figure 10 A).

After 12-week of topical phytotherapeutic treatment, the improvements of pain and performance parameters and the percentages of improvements were observed: pain in the right leg (94.91), left leg (94.87) and lower back (93.62) under Visual Analogue Scale (VAS)²⁸ and pain (88.23), stiffness (84.71) and physical function (74.07) under WOMAC Index²⁹ and parameters under Oswestry Disability index (ODI)³⁰ (74.47), Lower Extremity Functional Scale (LEFS)³¹ (62.50), and Karnofsky Performance Scale (KPS)³² (80.00) as well as the reduction of obesity as confirmed by Body Mass Index (BMI)³³ (11.93) (Figures 1-9), evidenced by X-ray imaging as assessed by KL grading scale³⁴ wherein the gradation was improved from ≥ 4 at pre-treatment to ≥ 2 at post-treatment (Figure 10B).

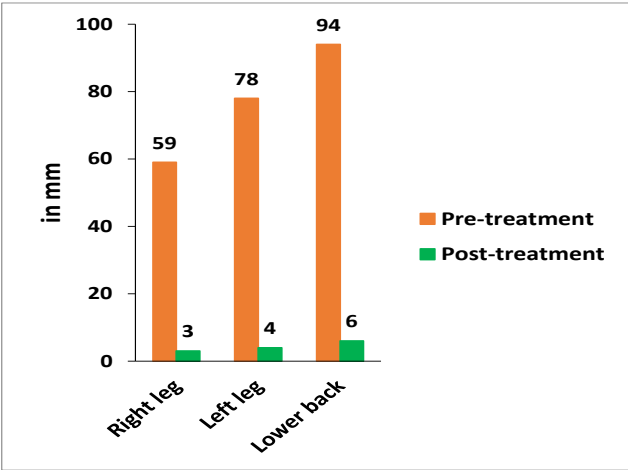


Figure 1: Comparative study of pre- and post-treatment of pain under VAS

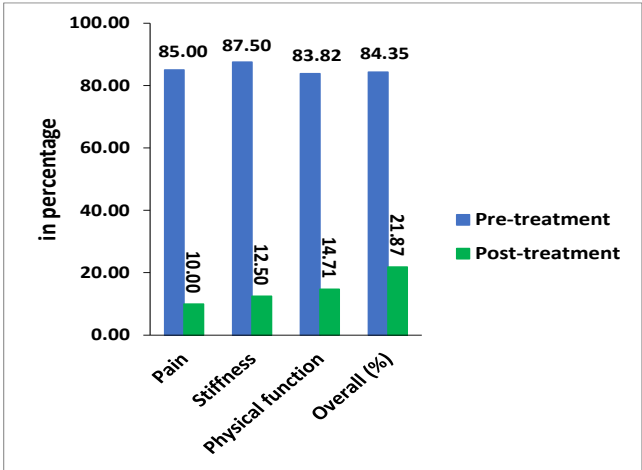


Figure 2: Comparative study of pre- and post-treatment of pain parameters under WOMAC index

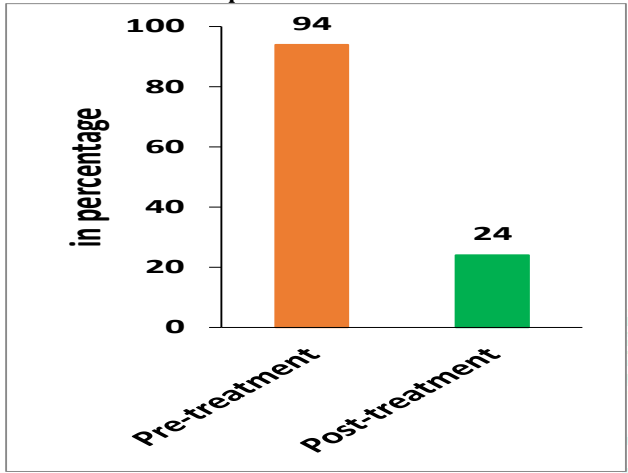


Figure 3: Comparative study of pre- and post-treatment of parameters under ODI

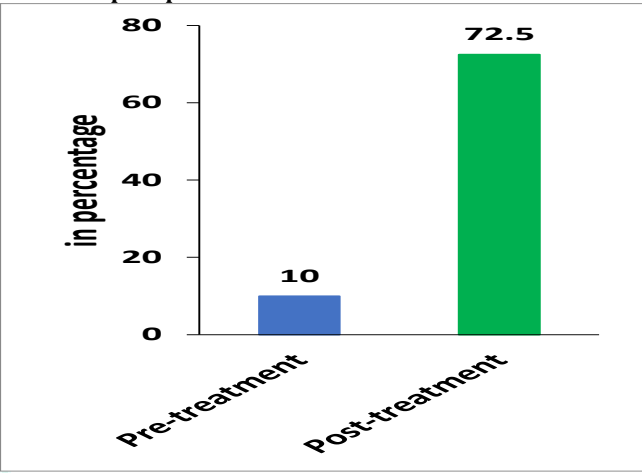


Figure 4: Comparative study of pre- and post-treatment of parameters under LEFS

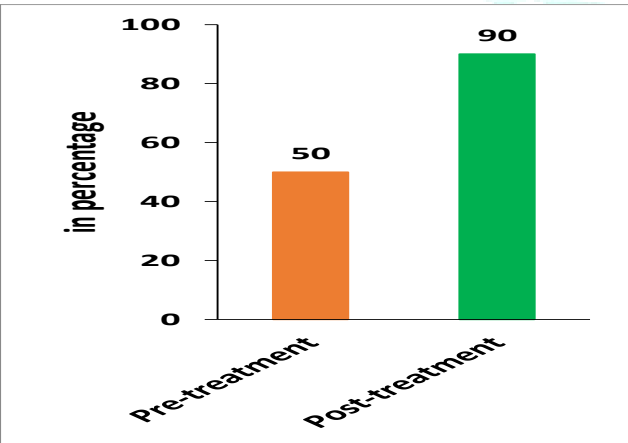


Figure 5: Comparative study of pre- and post-treatment of performance parameters under KPS

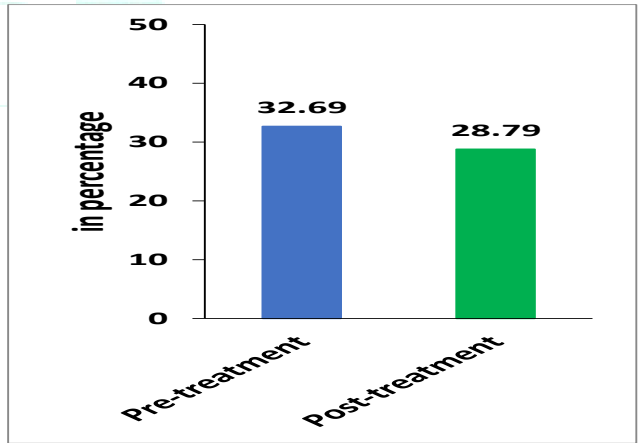


Figure 6: Comparative study of pre- and post-treatment of body-weight under BMI

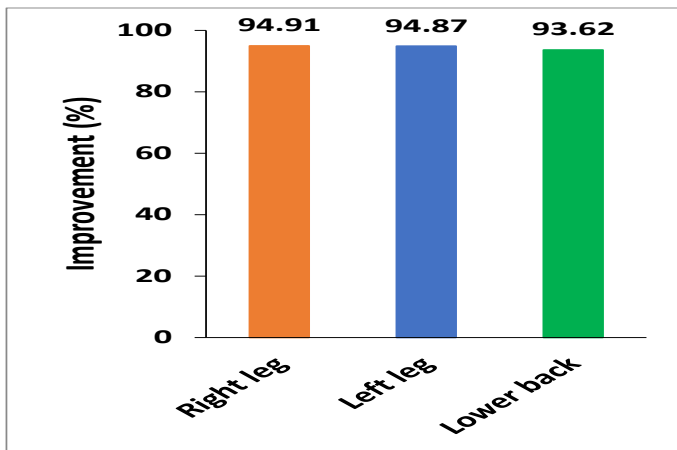


Figure 7: % of improvement after post-treatment under VAS

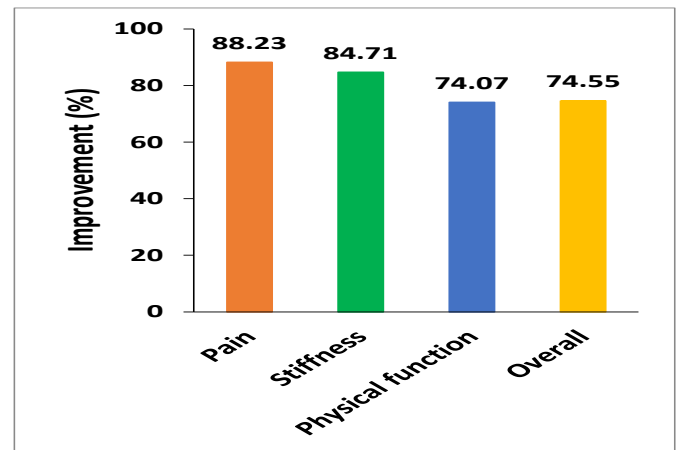


Figure 8: % of improvement after post-treatment under WOMAC index

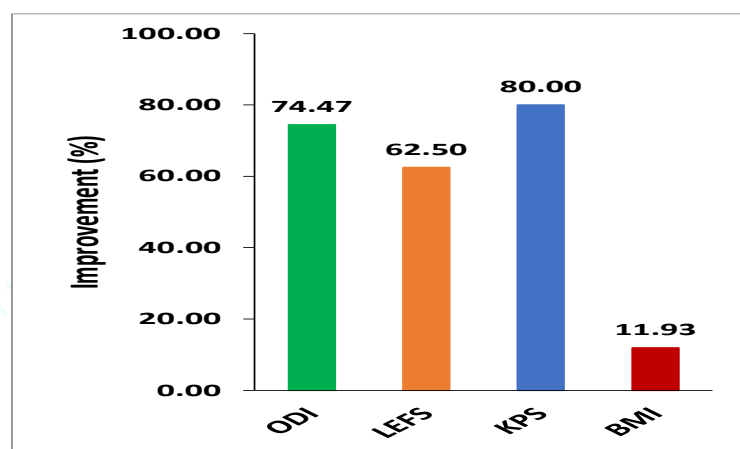


Figure 9: % of improvement after post-treatment under ODI, LEFS, KPS, BMI

Age: 45 Years, Sex: Male

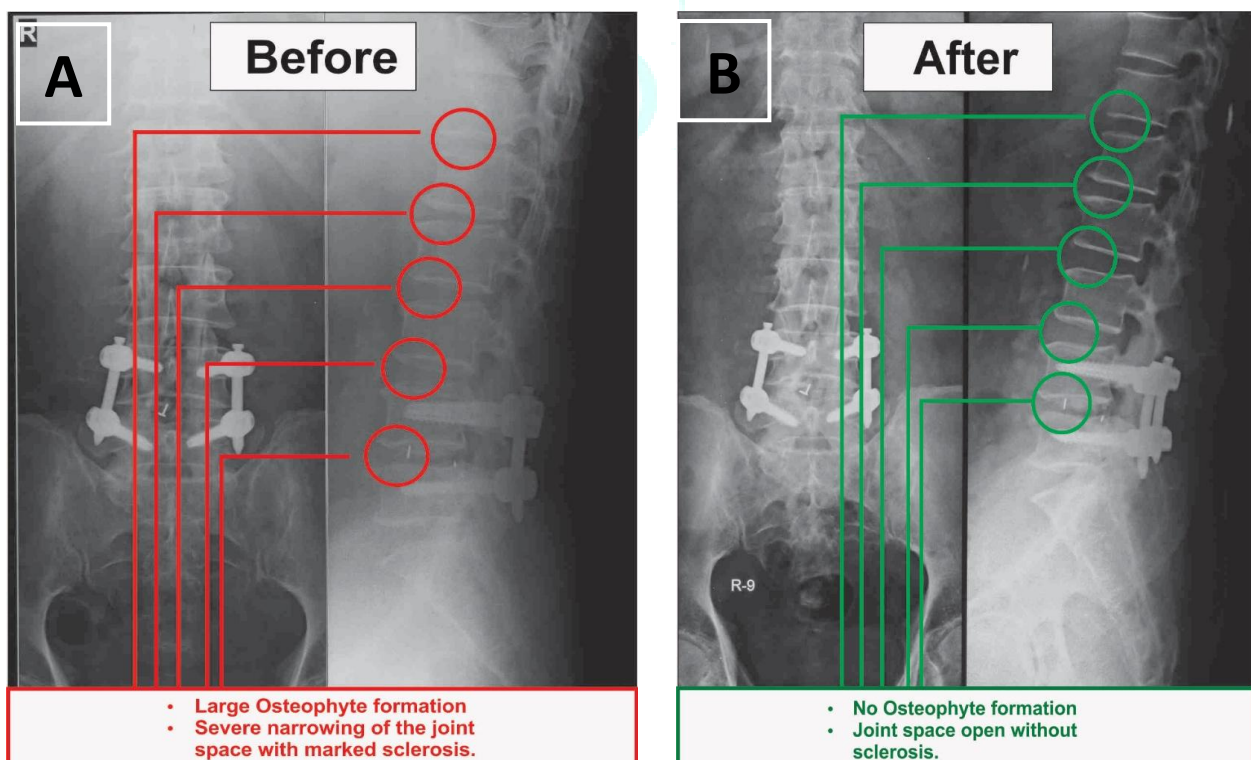


Figure 10: Radiographic images of before and after the treatment of lumbar spine

DISCUSSION

The present case report indicates the failure in spine surgery for LSD with pain and non-performance of daily activities, alternative treatment with specialised topical phytotherapy for 12-week would be best. Generally, the spine surgery for slipped disc supports to relief pain and improvement of performance in daily activities. Further revision on failed spine surgery may be stressful, risk and expensive but specialized topical phytotherapeutic treatment after 12-week to the studied patient is the suitable therapy where substantial percentages of improvements in pain, stiffness, functional and performance abilities under VAS, WOMAC index, ODI, LEFS, KPS and BMI with highly noticeable (Table 2 and Figures 1-9).

CONCLUSION

The aim of the spine surgery for LSD is to reduce the pain, increase the functional ability and the compression between the lumbar vertebrae. From the results, it is firmly confirmed that the failed spine surgery for LSD can be treated effectively with the help of topical phytotherapeutic method within 12 weeks as evidenced by X-ray images and by diminishing pain, stiffness and improvement of physical functional and performance abilities under VAS, WOMAC index, ODI, LEFS, and KPS and obesity confirmed by BMI.

Further researches should be undertaken on:

1. Deranged anatomical and abnormal biochemical features after spine surgery.
2. Phytochemicals characterization by using Mass Spectroscopy.

Acknowledgments: The author acknowledges the assistance of Ayondeep Ganguly and Anondeep Ganguly for coordinating patients and arranging all data in the present study.

Conflicts of interest: The author declares that there are no conflicts of interest regarding the present study.

Funding: This research did not receive any specific grant from funding agencies in the public, commercial, or not-for-profit sectors.

REFERENCES

1. Heliovaara M, Risk factors for low back pain and sciatica, *Ann Med*, 1989; 21:257-264.
2. Wu ZS, Zhen S, Wang TY, Ye SB, Surgery 5th edn. In: Beijing: Ren Min Wei Sheng Chu Ban She; 2003. 875-878.
3. Pan HJ. Biomechanics analysis on lumbar intervertebral nucleus pulposus outstanding disease, *China J Spor Med*, 2002; 21:138-140.
4. Freynhagen R, Baron R, Gockel U, Tolle TR, PainDETECT: A new screening questionnaire to identify neuropathic components in patients with back pain. *Curr Med Res Opin*, 2006; 22:1911-1920.
5. Hoy D, Bain C, Williams G, March L, Brooks P, et al. A systematic review of the global prevalence of low back pain, *Arthritis Rheum*, 64; 2012; 2028-2037.
6. Chen R, Xiong J, Chi Z, Zhang B, Heat-sensitive moxibustion for lumbar disc herniation: a meta-analysis of randomized controlled trials, *J Tradit Chin Med*, 2012; 32:322-328.
7. Jain N, Slip disc with sciatica-Newer non-surgical treatment, *Journal of International Medical Sciences Academy*, 2013; 26:249-251.
8. Li Y, Fredrickson V, Resnick DK, How should we grade Lumbar disc herniation and nerve root compression? A systematic review, *Clin Orthop Relat Res*, 2015; 473:1896-1902.
9. Lawrence JS, Disc degeneration. Its frequency and relationship to symptoms, *Ann Rheum Dis*, 1969; 28:121-138.
10. Schmorl G, Junganns H, Die gesunde und kranke Wirbelsaule in Rontgenbild und Klinik. Gebundenes Buch; 1951.

11. Ganguly A, Ganguly D, Aberrant Biomarkers, Leg Anatomy and Pain Parameters are the Risk Factors in Lumbar-Herniated Disc: a Novel Diagnostic Protocol, *J Orthopedics Rheumatol*, 2018; 5(2):11.
12. Ganguly A, Ganguly D. Evidence-based tropical phytotherapeutic treatment protocol for lumbar slipped disc: An approach with biochemical, anatomical, functional disability and radiological parameters, *IOSR Journal of Dental and Medical Sciences*, 2018; 17(9):01-20.
13. Elgafy H, Vaccaro AR, Chapman JR, Dvorak MF, Rationale of revision lumbar spine surgery, *Global Spine J*, 2012; 2:7-14.
14. Ganguly A, Tropical phytotherapeutic treatment for achieving knee symmetry in osteoarthritis - A sustainable approach, *Int J Phytomedicine*, 2015a; 6:489-509.
15. Ganguly A, Obtaining normal flexion and extension of knee joints on supine, prone and standing position in osteoarthritis by topical phyto-therapeutic treatment irrespective of age and sex, *Int J Phytomedicine*, 2015b; 7:290-301.
16. Ganguly A, Normalization of varus/valgus deformities in osteoarthritis by external application of phytoconstituents: confirmed with anatomical observations and biochemical profiles and radiological images, *Anat Physiol*, 2016; 6:224.
17. Belcaro G, Dugall M, Luzzi R, Hosoi M, Ledda A, et al. Phytoproflex®: supplementary management of osteoarthritis: a supplement registry, *Minerva Med*, 2018; 109:88-94.
18. Wang Q, Pan X, Wong HH, Wagner CA, Lahey LJ, et al. Oral and topical boswellic acid attenuates mouse osteoarthritis, *Osteoarthritis and Cartilage*, 2014; 22:128-132.
19. Ramadan G, Al-Kahtani MA, El-Sayed WM, Anti-inflammatory and anti-oxidant properties of *Curcuma longa* (turmeric) versus *Zingiber officinale* (ginger) rhizomes in rat adjuvant-induced arthritis, *Inflammation*, 2010; 34:291-301.
20. Al-Bahtiti NH, A study of preservative effects of sesame oil (*Sesamum indicum* L.) on mashed potatoes, *Int J Sci Res Innovative Technol*, 2015; 2:6-10.
21. Berit D, Ingrid W, Anders B, Effect of active hand exercise and wax bath treatment in rheumatoid arthritis patients, *Arthritis Care Res*, 1992; 5:87-92.
22. Shah U, *Cissus quadrangularis* L.: phytochemicals, traditional uses and pharmacological activities - a review, *Int J Pharm Pharm Sci*, 2011; 3:41-44.
23. Kontogianni VG, Tomic G, Nikolic I, Nerantzaki AA, Sayyad N, et al. Phytochemical profile of *Rosmarinus officinalis* and *Salvia officinalis* extracts and correlation to their antioxidant and anti-proliferative activity, *Food Chem*, 2013; 136:120-129.
24. Singh S, Singh S, Singh AP, Phytochemical investigation of different plants parts of *Calotropis gigantea*, *Int J Sci Res Publ*, 2013; 3:1-3.
25. Singh S, Singh S, Mishra RM, Shrivastava MP, Preliminary phytochemical screening of *Calotropis gigantea* leaf, *Int J Sci Res Publ*, 2014; 4:1-3.
26. Ganguly A, Diagnosis, prevention & phytotherapy for osteoarthritic disorders: pain diagnostic parameters and prevention of OADs. Scholars press, UK; 2017. Pp. 17-33.
27. Ganguly A, Degenerative changes in lumber-region occur simultaneously with bilateral-osteoarthritic changes in knee-joints and vice-versa: normalization with topical application of phytoconstituents by specialized techniques involving possible cartilage- regeneration, *Int J Recent Sci Res*, 2015; 6:6331-6346.
28. Bodian CA, Freedman G, Hossain S, Eisenkraf JB. The visual analog scale for pain: Clinical significance in postoperative patients, *Anesthesiology*, 95, 2001, 1356-1361.
29. Bellamy N, Buchanan WW, Goldsmith CH, Campbell J, Stitt LW. Validation study of WOMAC: a health status instrument for measuring clinically important patient relevant outcomes to anti-rheumatic drug therapy in patients with osteoarthritis of the hip or knee. *J Rheumatol*.1988;15:1833-1840.
30. Fairbank JCT, Pynsent PB. The Oswestry Disability Index, *Spine*, 2000; 25(22):2940-2953.
31. Binkley JM, Stratford PW, Lott SA, Riddle DL. The Lower Extremity Functional Scale (LEFS): Scale development, measurement properties, and clinical application, *Physical Therapy*, 1999; 79:371-383.
32. Schag CC, Heinrich RL, Ganz PA. Karnofsky performance status revisited: Reliability, validity, and guidelines, *J Clin Oncology*, 1984; 2:187-193.
33. Ferrera LA, ed. Focus on Body Mass Index and Health Research. New York: Nova Science, 2006. ISBN 978-1-59454-963-2.
34. Kellgren JH, Lawrence JS. Radiological assessment of osteo-arthritis *Ann Rheum Dis*, 1957; 16:494-502.