

Open  Access

Research Article

Evolocumab in treatment of acute pancreatitis induced by hypertriglyceridemia

Kamel El-Reshaid *, Shaikha Al-Bader **, Zhaneta Markova***

*Department of Medicine, Faculty of Medicine, Kuwait University, P O Box 24923, 13110 Safat, Kuwait

** Department of Medicine, Nephrology unit, Amiri hospital, Ministry of health, Kuwait

***Department of Radiology, IMC, Kuwait

ABSTRACT

Acute pancreatitis (AP) is a common emergency resulting from inflammation of the pancreas. The mechanism involves premature activation of enzyme precursors in the acinar cells triggering a self-digestive inflammatory cascade. Hypertriglyceridemia is the most common etiology of pancreatitis after gall stones and alcohol. It usually follows a sudden surge such as diabetic ketoacidosis on top of hereditary hyperlipidemia. In the present case report; we describe a patient with type-I diabetes mellitus who had developed recurrent attacks of hypertriglyceridemia AP (HTG-AP) despite Fenfibrate-therapy and report on our experience with Evolocumab in his treatment and prophylaxis.

Keywords: diabetes mellitus, hypertriglyceridemia, pancreatitis, prophylaxis, treatment.

Article Info: Received 11 Sep 2019; Review Completed 21 Oct 2019; Accepted 26 Oct 2019; Available online 15 Nov 2019



Cite this article as:

El-Reshaid K, Al-Bader S, Markova Z, Evolocumab in treatment of acute pancreatitis induced by hypertriglyceridemia, Journal of Drug Delivery and Therapeutics. 2019; 9(6):135-139 <http://dx.doi.org/10.22270/jddt.v9i6.3717>

*Address for Correspondence:

Dr. Kamel El-Reshaid, Professor, Dept. Of Medicine, Faculty of Medicine, Kuwait University, P O Box 24923, 13110 Safat, Kuwait

INTRODUCTION

Acute pancreatitis (AP) is a common emergency resulting from inflammation of the pancreas. It presents with the cardinal features of acute upper abdominal pain radiating to the back, elevated levels of the pancreatic enzymes amylase and lipase, and characteristic features on imaging [1]. The mechanism involves premature activation of enzyme precursors in the acinar cells triggering a self-digestive inflammatory cascade. Pancreatic enzymes such as trypsinogen are synthesized and stored in an inactive – hence harmless – form, and are activated upon release into the lumen of the duodenum via the action of enterokinases [2]. Premature activation may occur for a variety of reasons with gall stones and alcohol being the most common. Genetic factors, toxins (alcohol and organophosphate insecticides), drugs (steroids, thiazides, beta-blockers, protease inhibitors, azathioprine and DPP-4 anti-diabetic agents), metabolic (hypercalcemia, obesity, hypothyroidism and hypertriglyceridemia), structural damage to pancreatic duct post-ERCP and infections (mumps) account for the rest [3]. Hyperlipidemia in the form of hypertriglyceridemia or chylomicronemia, accounts for 7% of the AP cases and is the most common after gall stones and alcohol [4]. In the

present case report; we describe a patient who had recurrent attacks of hypertriglyceridemia AP (HTG-AP) and provide a useful measure of treatment and prophylaxis.

THE CASE:

A 30-year-man presented with severe and progressive epigastric pain radiating to the back for 1 week. The latter was associated with recurrent vomiting, abdominal distension and inability to lie down. He had similar attacks in the past 6 months. His family members had similar history and hyperlipidemia. His body weight was 60 kg. He was afebrile with blood pressure at 110/70 mm Hg with postural hypotension. He had tender and rigid epigastrium, with diminished bowel sounds. Laboratory investigations; showed peripheral leukocytic count at $16 \times 10^9/L$ with 90% neutrophils with normal platelets counts and hemoglobin. Serum sugar was 20 mmol/L. Serum urea, creatinine, electrolytes and liver functions were normal including albumin and bicarbonate. TSH was normal. The serum was lipemic with total cholesterol at 12 mmol/L, Low-density lipoprotein (LDL) cholesterol at 8 mmol/L and triglycerides 22 mmol/L. Serum amylase was mildly elevated at 170 IU/L (Normal: 25-130) yet serum lipase was very high at 834 IU/L (Normal: 13-60). Urine routine and microscopy revealed 4

(+) glucose yet without ketoneuria, proteinuria, hematuria and pyuria. Ultrasound of the abdomen showed an enlarged and edematous pancreas with smooth, ill-defined margins, and pancreatic pseudocyst. The gall bladder and common bile duct were normal and without stones. Computed tomogram of the abdomen confirmed the findings and confirmed the absence of gall stones and tumor [Figure 1]. The patient was treated conservatively with nasogastric suction, intravenous fluids, broad-spectrum antibiotic prophylaxis and narcotics for pain control. Serum glucose was controlled with insulin drip. On the basis of his high triglycerides, cholesterol, and VLDL cholesterol, a diagnosis of type IIb hyperlipoproteinemia (Familial Combined Hyperlipidemia / FCHL) was established. He received

Evolocumab (Repatha-Amgen-pharmaceutical comp.) at a dose of 140 ug subcutaneously every week. Within few days, the patient had improved was discharged on Lantos at night and pre-meals Novorapid injections as well as weekly Evolocumab. By the third week, CT scan of the abdomen showed marked improvement his pancreatitis and reduction in the size of his pancreatic pseudocyst (Fig. 2). Six weeks later; the dose of Evolocumab was spaced to the usual dose of 140 ug every 2 weeks. Subsequently; the patient did not have any further AP and his lipid profile remained normal (Table 1). Follow up; CT of the abdomen showed complete resolution of his pancreatic disease and its pseudocystic formation by 3 months (Fig. 3).

Table 1. Flow chart showing the laboratory parameters during management of the patient with acute pancreatitis (AP).

| Serum test | 6-months before (Previous AP) | 6-weeks before | On admission (Present AP) | On Evolocumab 140 ug/week | | On Evolocumab 140 ug/2 weeks |
|---|--|-------------------|------------------------------------|------------------------------|------------------|---------------------------------|
| | | | | 3-weeks later | 6-weeks later | 3-months later |
| Amylase (25-130 IU/L) | 140 | 55 | 170 | 60 | 70 | 40 |
| Lipase (13-60 IU/L) | 340 | 60 | 834 | 140 | 40 | 30 |
| Triglyceride (0.5-1.3 mmol/L) | 10 | 4 | 22 | 3 | 2.5 | 1.2 |
| Total cholesterol (3-5 mmol/L) | 8 | 6 | 12 | 4 | 1.8 | 2 |
| LDL- Cholesterol (2-4 mmol/L) | 5 | 4 | 8 | 3 | 0 | 0.5 |
| Fasting glucose (4-6 mmol/L) | 17 | 8 | 20 | 6 | 4 | 5 |

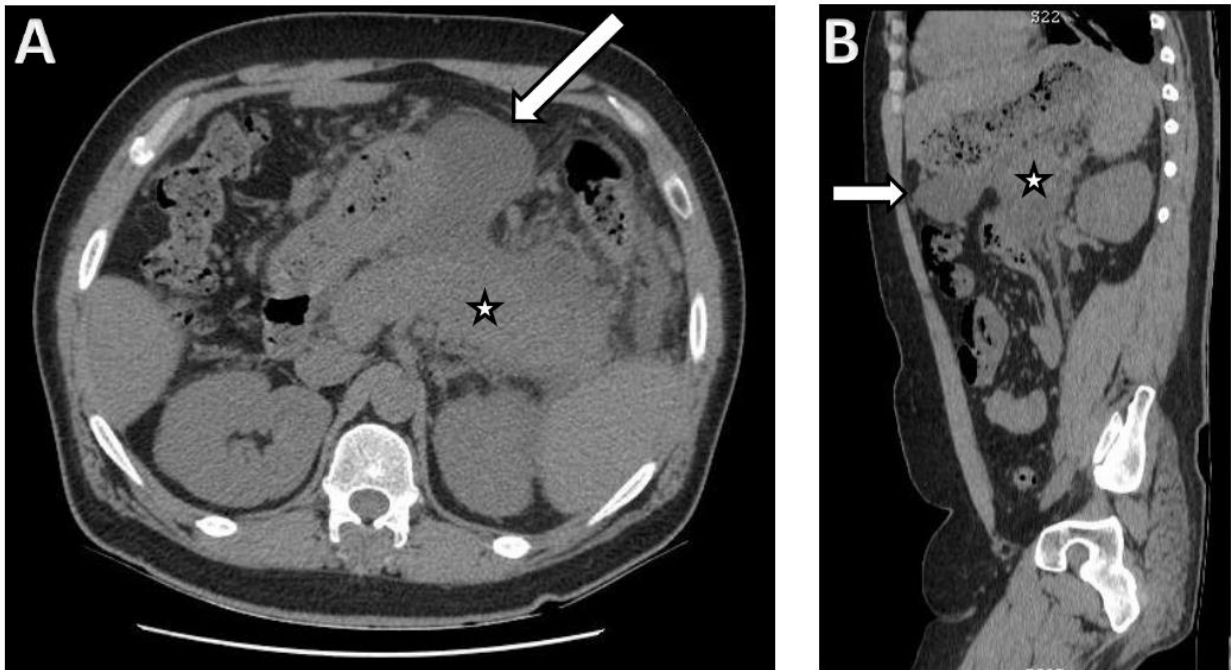


Figure 1. Figure 1. Axial (A) and sagittal (B) planes of CT scan of the patient's abdomen on his initial assessment showing an enlarged pancreas (Star) with indistinct margins and reduced density (due to oedema) with surrounding fat stranding and thickened Gerota's fascia. Note the large pancreatic pseudocyst which is a non-capsulated homogenous peripancreatic fluid collection (solid arrow).

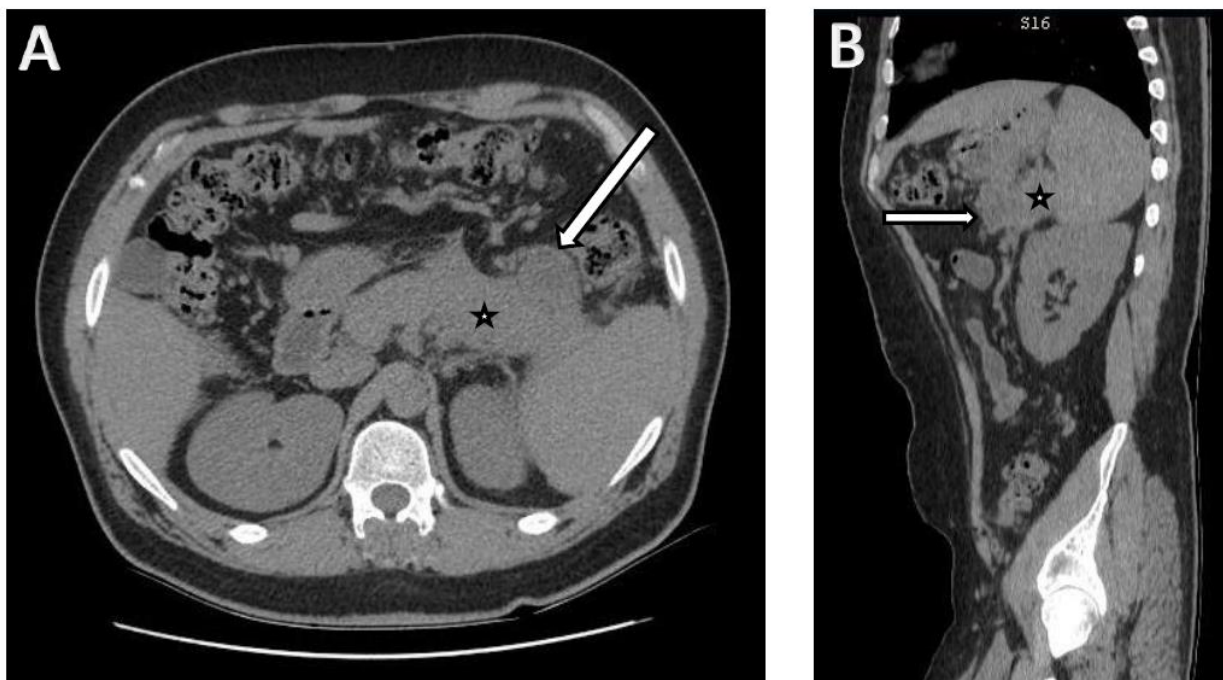


Figure 2. Figure 2. Axial (A) and sagittal (B) planes of CT scan of the patient's abdomen, 3 weeks after Evolocumab treatment, showing reduction of pancreatic inflammation (star) and the pancreatic pseudocyst (arrow) sizes.

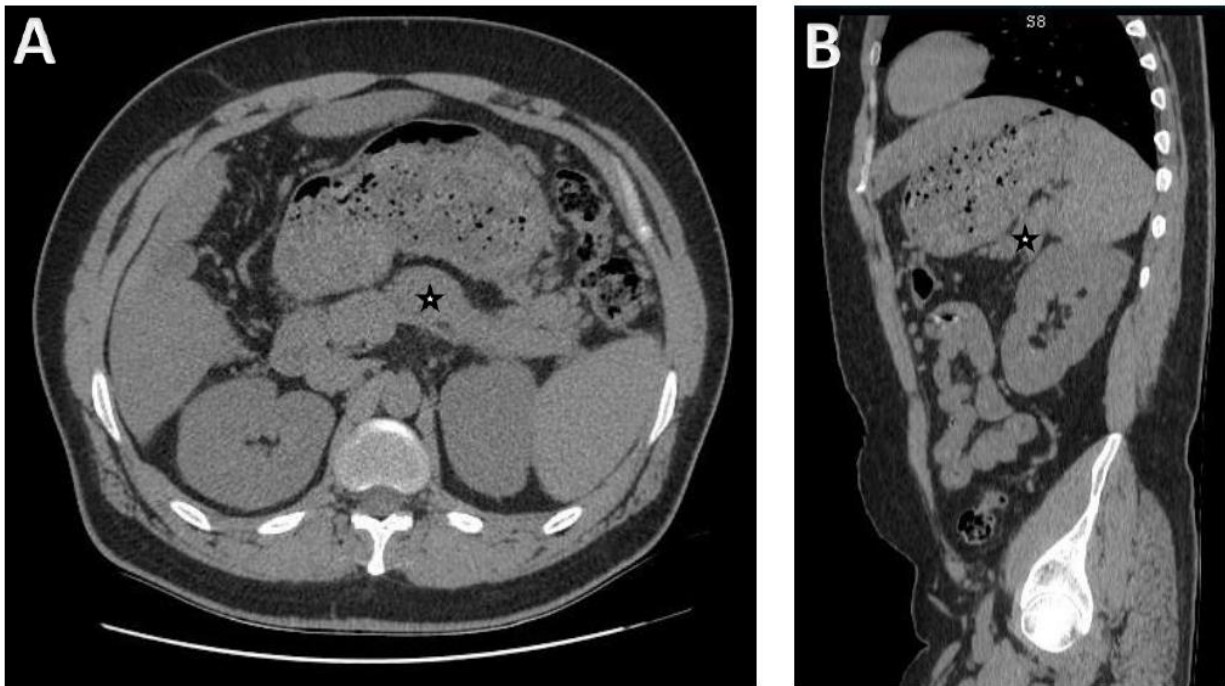


Figure 3. Figure 3. Axial (A) and sagittal (B) planes of CT scan of the patient's abdomen, 3 months after Evolocumab treatment, showing near normal pancreatic structures (star).

DISCUSSION

Primary hyperlipidemia is a rare hereditary diseases associated with defects in catabolism of lipids. They are classified according to the Fredrickson classification, which is based on the pattern of lipoproteins on electrophoresis or ultracentrifugation [5]. Our patient had type IIb hyperlipoproteinemia (Familial Combined Hyperlipidemia) and his AP was precipitated by secondary hyperlipidemic surges due to severe hyperglycemia. HTG-AP is rarely seen at levels less than 1,000mg/dL (11.3 mmol/L) [6]. Such levels are not seen with secondary causes and hence, a primary hyperlipidemic syndrome should be suspected as an underlying defect with the secondary cause as a facilitator. With secondary insults in a genetically predisposed individual; triglycerides levels exceed 1,000mg/dL and chylomicrons are almost always present. The latter low density particles are very large and can obstruct capillaries leading to local ischemia. This local damage can expose triglycerides to pancreatic lipases. Subsequently, triglycerides are degraded to free fatty acids which initiate the cytotoxic injury via the inflammatory mediators and free radicals [7]. Interestingly, serum amylase may be normal (in 10% of cases) for cases of acute or chronic pancreatitis (depleted acinar cell mass) [8].

The initial conservative management of HTG-AP includes; bowel rest, intravenous fluids, and analgesia [9]. However, rapid lowering of hyperlipidemia is essential to slow the progression of disease. It can be achieved by correction of secondary insult/s and hypolipemic measures. In our patients; control of diabetes by insulin activates catabolism of TG by activation of Lipoprotein lipase [10]. The other hypolipemic measures include; Fibrates, Statins, Niacin and heparin. Unfortunately, Niacin and Heparin have limited role in control of fulminant disease. Fibrates are considered the standard treatment of HTG-AP yet subsequent addition of Statins, for hypercholesterolemia, increases the risk of rhabdomyolysis [11]. Moreover, since Fibrates are oral agents; their benefit is limited in the initial treatment of HTG-AP since patients have to be kept on NG suction. Direct

removal of lipoproteins by plasmapheresis can be used in patients unresponsive to drug therapy [12]. However, plasmapheresis is expensive and is limited to large medical centers. Since, our patient had severe HTG-AP we elected to treat him with Evolocumab yet with a modified regimen. We used it every week rather than every 2 weeks to ensure faster action. Our method was safe and efficacious. It decreased the severity of the disease leading to shorter duration of illness and less patient's suffering as well as rapid clearance of its complications (pseudocyst formation).

Evolocumab is a fully human monoclonal antibody that inhibits proprotein convertase subtilisin/kexin type 9 (PCSK9). The latter is a protein that targets LDL receptors for degradation and thereby reduces the liver's ability to remove LDL-cholesterol from the blood and can reduce triglyceride levels by as much as 70% if given every 2 weeks [13]. It is a product of Amgen-pharmaceutical company that has been approved by the FDA in 2105 [14]. The efficacy of the drug and its safety, in ischemic heart disease, has been established in recent clinical studies [15]. However, its use in prevention of TG-induced AP has not been reported.

CONCLUSION:

Our case report is the first attempt to use Evolocumab in treatment of severe TG-induced AP.

REFERENCES:

- 1- Whitcomb D. Acute Pancreatitis. *N Engl J Med* 2006; 354:2142-215.
- 2- Dominguez-Munoz JE, Malfertheiner P, Ditschuneit HH, Blanco-Chavez J, Uhl W, Buchler M, et al. Hyperlipidemia in acute pancreatitis. Relationship with etiology, onset and severity of the disease. *Int J Pancreatol* 1991; 10:261-267.
- 3- Whitcomb DC, Yadav D, Adam S, et al. North American Pancreatic Study Group. Multicenter approach to recurrent acute and chronic pancreatitis in the United States: the North American Pancreatitis Study 2 (NAPS2). *Pancreatology* 2008; 8:520-531.

- 4- Seales CE, Ooi TC. Underrecognition of chylomicronemia as a cause of acute pancreatitis. *CMAJ* 1992; 147:1806-1808.
- 5- Fredrickson, DS; Lees, RS (1965). A system for phenotyping hyperlipoproteinemia. *Circulation* 1965; 31:321-327
- 6- Lithell H, Vessby B, Walldius G, Carlson LA. Hypertriglyceridemia-acute pancreatitis-ischemic heart disease. A case study in a pair of monozygotic twins. *Acta Med Scand* 1987; 221:311-316.
- 7- Kimura W, Mossner J. Role of hypertriglyceridemia in the pathogenesis of experimental acute pancreatitis in rats. *Int J Pancreatol* 1996; 20:177-184
- 8- Smotkin J, Tenner S. Laboratory diagnostic tests in acute pancreatitis. *J Clin Gastroenterol* 2002; 34:459-462.
- 9- Joshua A, Greenberg JA, Hsu J, Bawazeer M, Marshall J, Friedrich JO, Cobrun N, May GR, Pearsall E, McLead RS. Clinical practice guideline: management of acute pancreatitis. *Can J Surg* 2016; 59:128-140.
- 10- Rubins HB, Robins SJ, Collins D, Nelson DB, Elam MB, Schaefer EJ, et al. Diabetes, plasma insulin and cardiovascular disease: Subgroup analysis from the Department of Veterans Affairs high density lipoprotein intervention trial (VA-HIT) *Arch Intern Med* 2002; 162: 2597-2604.
- 11- Frick MH, Elo O, Haapa K, Heinonen OP, Heinsalmi P, Helo P, et al. Helsinki Heart Study: Primary-prevention trial with gemfibrozil in middle aged men with dyslipidemia. Safety of treatment, changes in risk factors and incidence of coronary heart disease. *N Engl J Med* 1987; 317:1237-1245.
- 12- Yeh JH, Chen JH, Chiu HC. Plasmapheresis for hyperlipidemic pancreatitis. *J Clin Apheresis* 2003; 18:181-185
- 13- Weinreich, M; Frishman, W. "Antihyperlipidemic therapies targeting PCSK9". *Cardiology in Review* 2014; 22:140-6.
- 14- FDA News Release (August 27, 2015). FDA approves Repatha to treat certain patients with high cholesterol. U.S. Food and Drug Administration. Retrieved 30 August 2015.
- 15- Sabatine MS, Giugliano RP, Keech, AC, Honarpour N, Wiviott SD, Murphy SA, Kuder JF, Wang H, Liu T. "Evolocumab and Clinical Outcomes in Patients with Cardiovascular Disease. *N England J Med* 2017; 376:1713-1722.

Journal of Drug Delivery & Therapeutics



JDDT