

Available online on 15.08.2019 at <http://jddtonline.info>

Journal of Drug Delivery and Therapeutics

Open Access to Pharmaceutical and Medical Research

© 2011-18, publisher and licensee JDDT, This is an Open Access article which permits unrestricted non-commercial use, provided the original work is properly cited

Open  Access

Research Article

Hepatoprotective Effect of *Tagetes Erecta* L. Extract on Carbon Tetrachloride Induced Hepatotoxicity in Rats

Kamshetti Manoj Vidyadhar, Hemant Kumar Sharma

College of Pharmacy, Sri Satya Sai University of Technology & Medical Sciences, Sehore-466001, Madhya Pradesh

ABSTRACT

Tagetes erecta L. is a widespread garden plant that is commonly known as the marigold, and it is widely used as a medicinal herb for its anti-inflammatory, analgesic, and anti-edematous properties, which are important for phytotherapeutic, dermatological and cosmetic applications. In this study, the protective effects of water extract of *Tagetes erecta* L. against liver damage were evaluated in carbon tetrachloride (CCl₄)-induced chronic hepatotoxicity in rats. The results showed that the treatment of extract significantly lowered the CCl₄-induced serum levels of hepatic enzyme markers (GOT, GPT, ALP, and total bilirubin). Liver histopathology showed that extract reduced the incidence of liver lesions including hepatic cells cloudy swelling, lymphocytes infiltration, hepatic necrosis, and fibrous connective tissue proliferation induced by CCl₄ in rats. Therefore, the results of this study suggest that *Tagetes erecta* L. Extract could protect liver against the CCl₄-induced oxidative damage in rats, and this hepatoprotective effect might be contributed to its modulation on detoxification enzymes and its antioxidant and free radical scavenger effects.

Keywords: *Tagetes erecta* L., Carbon Tetrachloride, Liver Damage, Hepato-protection

Article Info: Received 18 June 2019; Review Completed 24 July 2019; Accepted 30 July 2019; Available online 15 August 2019



Cite this article as:

Vidyadhar KM, Sharma HK, Hepatoprotective Effect of *Tagetes Erecta* L. Extract on Carbon Tetrachloride Induced Hepatotoxicity in Rats., Journal of Drug Delivery and Therapeutics. 2019; 9(4-s):269-272
<http://dx.doi.org/10.22270/jddt.v9i4-s.3316>

***Address for Correspondence:** Dr. Hemant Kumar Sharma, Dean, College of Pharmacy, SSSUTMS, Sehore, M.P.

INTRODUCTION

The liver is the most important organ that plays an important role in maintaining various physiological processes in the body. It is involved in several vital functions, such as metabolism, secretion, and storage. It plays a central role in the detoxification and excretion of many exogenous and endogenous compounds¹. Hence, any injury to it or impairment of its function has grave implications for the health of the affected person. Every year, about 18,000 people are reported to die due to liver cirrhosis caused by hepatitis, although viral infection is one of the main causes for hepatic injury². It acts as a storage depot for proteins, glycogen, various vitamins, and metals. It also has a role in the regulation of blood volume by transferring the blood from the portal to the systemic circulation and its reticulo-endothelial system and participates in the immune mechanism. Medicinal plants are important sources of hepatoprotective bioactives³. *Tagetes erecta* L. is a widespread garden plant that is commonly known as the marigold, and it is widely used as a medicinal herb for its anti-inflammatory, analgesic, and anti-edematous properties, which are important for phytotherapeutic, dermatological and cosmetic applications^{4,5}. Essential oil from marigold has been shown to be an effective free radical scavenger, and the ethanol extract is reportedly effective against parakeratosis^{5,6}. This plant is rich source of alkaloids, volatile oils and

flavonoids⁷⁻⁸. The antioxidant activity of flavonoids depends upon the arrangement of functional groups about the nuclear structure. The configuration, substitution, and total number of hydroxyl groups substantially influence several mechanisms of antioxidant activity such as radical scavenging and metal ion chelation ability⁹⁻¹¹. The present work was focused to evaluate hepatoprotective effect of *Tagetes erecta* L. Flower extract against carbon tetrachloride induced hepatocellular damage in rats.

MATERIALS AND METHODS

Chemicals

All the solvents used in the study were purchased from CDH, India. All the other chemicals used in the study were of analytical grade. Silymarin was obtained from Micro Labs, India. Double distilled water was used in the study.

Collection, Identification and Extraction Of Flowers

The flowers of *Tagetes erecta* were obtained from local market, and it was authenticated by Dr. Ziaul Hasan, Head of Department, Department of Botany, Safia Science College, Bhopal, and a specimen voucher (500/Bot/Safia/14), deposited in the Department of Pharmacology, Sapience Bioanalytical Research Lab, Bhopal, for future reference. Thus obtained flowers were cleaned from dust and other materials, and then it was dried under the shade for 15 days.

The dried flowers were pulverized in an electric grinder. The powdered plant materials were subjected to maceration. The powdered material was soaked in 90% ethanol for four days. Stirring of the mixture was done twice daily. After the fourth day, the mixture was filtered and the marc was pressed. This process was repeated three times. The entire alcoholic fraction was combined and the ethanol was subjected for evaporation. The syrupy consistency material obtained was heated on the water bath until dry extract was obtained. Thus obtained ethanolic extract of flowers of *Tagetes erecta* was labeled and stored in the desiccator till further usage.

Preliminary Qualitative Phytochemical Analysis

The ethanolic extract of flowers of *Tagetes erecta* were subjected to qualitative examination for different phytoconstituents like alkaloids, carbohydrates, flavonoids, proteins, saponins, terpenoids and steroids by using standard methods¹².

Animals

Wister albino rats of either sex weighing between 180-200 g of either sex were used for the study. Animals were procured from the authorized animal house of Sapience Bioanalytical Research Lab, Bhopal, Madhya Pradesh. These animals were used for the acute toxicity and hepato-protective activity. The animals were stabilized for one week; they were maintained in standard condition at room temp; 60±5% relative humidity and 12 h light dark cycle. They had been given standard pellet diet supplied by Hindustan lever Co. Mumbai and water ad libitum throughout the course of the study. The animals were handled gently to avoid giving them too much stress, which could result in an increased adrenal output.

Assessment of Acute Toxicity

The preliminary pharmacological studies were conducted to assess the acute pharmacological effects and LD₅₀ of the ethanolic drug extract. The acute toxicity study was carried out in adult female albino rats by "up and down" method^[13]. The animals were fasted overnight and next day extract of the flowers of the plant *Tagetes erecta* (suspended in 0.6% w/v sodium CMC) were administered orally at different dose level (100 mg/kg-2000mg/kg). Then the animals were observed continuously for three hour for general behavioral, neurological, autonomic profiles and then every 30 min for next three hour and finally death after 24 hour. The LD₅₀ value will be determined by the graphic method.

Hepatoprotective Activity

This experiment was carried out as according to described by Akram jamshidzadeh et al. Wister rats (200-250g) of male, 20 weeks old were used; the rats were maintained at controlled temperature, 12 hours light/12 hours dark condition for 1 week before the start of the experiment. Rats were divided into six groups of four animals in each group^[14]. The treatment was carried out for seven days

Group I : Saline (10 ml/kg, i.p) as normal control for seven days.

Group II : CCl₄ in Olive oil (1:1, 3ml/kg, i.p.)

Group III : CCl₄ in Olive oil + Silymarin suspended in 0.6% C.M.C. (100 mg/kg, orally).

Group IV : CCl₄ in Olive oil + *Tagetes erecta* L extract (100 mg/kg, orally)

Group V : CCl₄ in Olive oil + *Tagetes erecta* L extract (200 mg/kg, orally)

Group VI : CCl₄ in Olive oil + *Tagetes erecta* L extract (400 mg/kg, orally)

Biochemical Estimation

The rats of all groups were scarified 48 hour after CCl₄ injection. They were anaesthetized by diethyl ether and blood was collected from retro- orbital route, and serum was separated for assessment of different enzymes level (SGPT, SGOT, & ALP) and bilirubin using kits.

Histopathological analysis

The liver will be preserved in 10% formalin solution for histopathological investigation.

Statistical analysis

All the values were expressed as mean ± SEM. Statistics was applied using Graph Pad Prism version 5.0 for Windows, Graph Pad software, San Diego, California, USA. One-way ANOVA followed by Dunnet's comparison test was used to determine the statistical significance between various groups. Differences were considered to be statistically significant when *p < 0.05; **p < 0.01, ***p < 0.001.

RESULTS AND DISCUSSION

Phytochemical Screening

The results of phytochemical screening indicated the presence of alkaloids, glycosides, flavonoids, tannins, steroids and carbohydrates in the extract.

Acute Toxicity Studies

The alcoholic extract of flowers of *Tagetes erecta* was found to be safe up to 2000 mg/kg body wt. by oral route. After 24 h animals were found well tolerated. There was no mortality and no signs of toxicity and extract were found to be safe, so three dose levels i.e. 100 mg/kg, 200mg/kg, 400mg/kg body weight were selected for hepatoprotective study.

Hepatoprotective Effect

Carbon tetrachloride intoxication in normal rats elevated the serum levels of SGOT, SGPT, ALP, and total bilirubin. The rats of all the three groups treated with alcoholic extract of *Tagetes erecta* at different dose levels showed significant reduction in SGOT, SGPT, ALP, and total bilirubin compared to the CCl₄ treated group. The result obtained so are statically significant and comparable to the silymarin treated group as shown in the Table 1.

Table 1: Effect Of Ethanolic Extract Of Flowers Of *Tagetes Erecta* On Biochemical Profile Of Animals With Ccl₄ Induced Hepatic Injury.

Groups	SGOT	SGPT	ALP	TOTAL BILURUBIN
Group I	95.30±1.59	48.55±1.21	126.15±1.82	0.99±0.01
Group II	481.00±1.80*	296.46±1.46*	250.50±1.80	4.23±0.02*
Group III	131.75±1.61*	57.77±2.10*	91.79±2.92*	1.24±0.02*
Group IV	353.72±1.59*	117.21±2.30*	181.28±1.90*	2.89±0.02*
Group V	221.91±1.63*	89.09±0.87*	122.98±1.72*	2.08±0.01*
Group VI	152.60±1.72*	71.41±1.90*	81.84±1.90*	1.55±0.01*

SGOT

SGOT in CCl₄ treated group have significantly reduced compared to control group. The values were increased up to 481 ± 1.80 ($p < 0.01$), compared to control group 95.30 ± 1.59 . SGOT were decreased significantly in treatment group up to 353.72 ± 1.59 ($p < 0.01$), 221.91 ± 1.63 ($p < 0.01$), and 152.60 ± 1.72 ($p < 0.01$), at doses of 100, 200 and 400 mg/kg body wt. respectively as compared to the only CCl₄ treated group. Silymarin also have decreased SGOT levels to 131.75 ± 1.61 ($p < 0.01$) (Table 1).

SGPT

Serum enzyme SGPT levels increased significantly in CCl₄ treated group as compare to the control rats. The values were increased up to 296.46 ± 1.46 ($p < 0.01$), compare to control group, which was 48.55 ± 2.25 . The SGPT were decreased significantly in treatment group up to 117.21 ± 2.30 ($p < 0.01$), 89.09 ± 0.87 ($p < 0.01$), 71.41 ± 1.90 ($p < 0.01$) at doses of 100, 200 and 400 mg/kg body wt. respectively as compared to the only CCl₄ treated group. Silymarin also have decreased the serum SGPT levels to 131.75 ± 1.61 ($p < 0.01$) (Table 1).

ALP

Serum ALP levels were increased significantly in CCl₄ treated group as compared to the control rats. The values were increased up to 250.50 ± 1.80 ($p < 0.01$), compare to control group which was 126.15 ± 1.82 . The serum ALP were decreased significantly in treatment group up to

181.28 ± 1.90 ($p < 0.01$), 122.98 ± 1.72 ($p < 0.01$), 81.84 ± 1.90 ($p < 0.01$) at doses of 100, 200 and 400 mg/kg body wt. respectively as compared to the CCl₄ treated group. Silymarin also have decreased the serum ALP levels to 91.79 ± 2.92 ($p < 0.01$) (Table 1).

Total Bilurubin

Total Bilurubin levels in CCl₄ treated group have significantly increased compare to control group. The values were increased up to 4.23 ± 0.02 ($p < 0.01$), compare to control group, which was 0.99 ± 0.01 . The serum total bilirubin values were reduced significantly in treatment group up to 2.89 ± 0.06 ($p < 0.01$), 2.08 ± 0.01 ($p < 0.01$), and 1.55 ± 0.01 ($p < 0.01$), at doses of 100, 200 and 400 mg/kg body wt. respectively as compared to the only CCl₄ treated group. Silymarin also have reduced serum total bilirubin levels to 1.24 ± 0.02 ($p < 0.01$) (Table 1).

Histopathological Analysis

The microscopic examination of liver of Group I showed a normal portal triad, sinusoids, and cord arrangement of hepatocytes. In group II, The microscopic examination of liver of this group showed marked to moderately severe fatty change of liver with presence of large fat vacuoles in the cytoplasm pushing the nuclei at the periphery. At place many fat vacuoles are seen united and are forming small fats cysts as well.

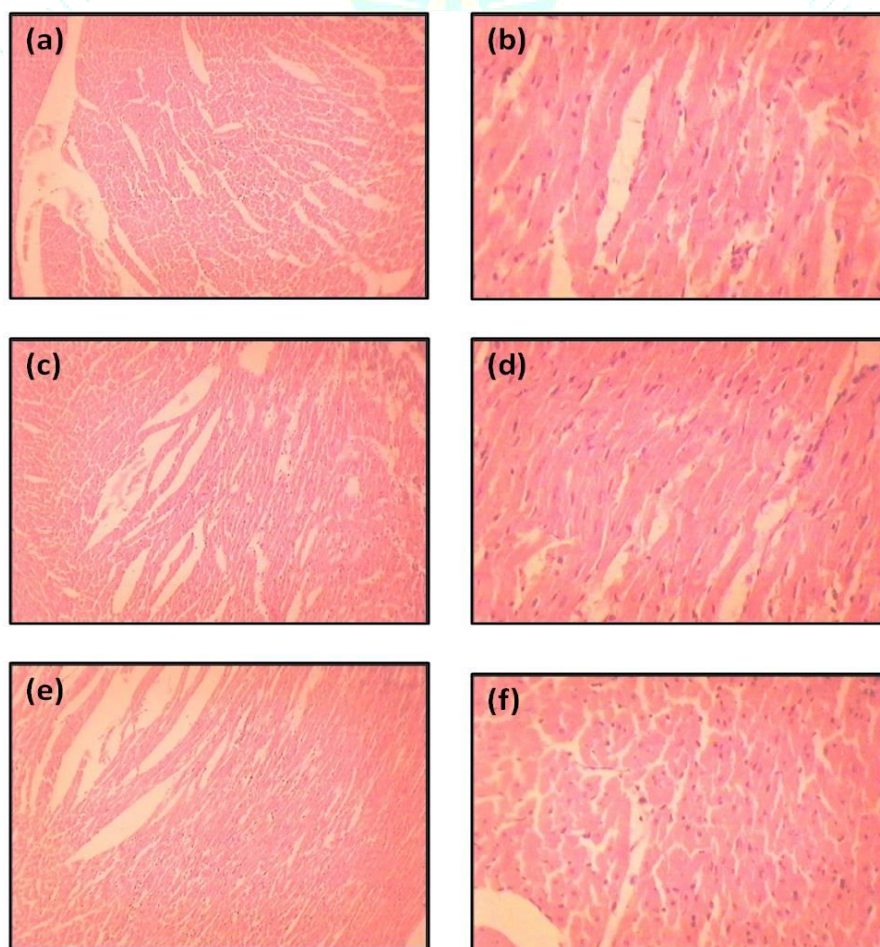


Figure 1: Histopathological analysis of various groups receiving CCl₄ and extract

In group III, The microscopic examination of liver of this group showed almost normal appearing hepatocytes and no

fatty change, or absence in hepatocytes. There is also no inflammation or necrosis. In group IV, : The microscopic

examination of liver of this group showed moderate degree of fatty change in the liver, however a fair number of normal hepatocytes are seen intermixed with fat laden hepatocytes. In group V, The microscopic examination of liver of this group revealed that the test drug when used in 100mg/kg body wt. was not able to provide proper protection from fatty change in liver as the section of liver at this dose showed moderately severe fatty change. In group VI, The microscopic examination of liver of this group revealed almost normal hepatocytes with only occasional fine fat vacuoles and mild inflammation was seen, this indicated that silymarin provided significant hepatoprotection from fatty change (Figure 1).

DISCUSSION

Liver plays a pivotal role in regulation of physiological processes. It is involved in several vital functions such as metabolism, secretion and storage, furthermore, detoxification of variety of drugs and xenobiotics occurs in liver. The bile secreted by the liver has, among other things, an important role in digestion. Liver disease is among the most serious ailments. They may be classified as acute or chronic hepatitis (inflammatory liver disease), hepatosis (non inflammatory disease) and cirrhosis (degenerative disorder resulting in fibrosis of the liver)¹⁵. Since it is involved in the biochemical conversion of various endogenous and exogenously administered / ingested substances, there is a possibility of generation of various highly reactive species of free radicals. However, it has an imbibit system like tissue glutathione (GSH), etc to scavenge them off. In spite of this the free radical generated by some hepatotoxins like CCl₄ may overpower the protective mechanism of the liver and cause hepatic damage. The hepatoprotective activity was assessed by measuring the biochemical markers like SGPT, SGOT, bilirubin (total and direct), and ALP in the CCl₄ induced hepatotoxic models¹⁶.

Subcutaneous administration of CCl₄ for two days has elevated the SGPT U/L (296.4), SGOT U/L (481.0), total bilirubin mg/dl (4.23), and ALP U/L (250.5). Pre-treatment with ethanolic extract (100,200 and 400mg/kg p.o) for 5 days has significantly reduced the elevated biochemical markers in a dose dependant manner. Treatment with 400 mg/ kg of ethanolic extract of flowers of *Tagetes erecta* has produced the hepatoprotective activity comparable to that of silymarin 25 mg/kg b.w. similarly CCl₄ has altered the liver architecture as indicated by the histopathological observation that moderate degree of fatty degeneration, ballooning of hepatocytes, presence of fatty cyst, infiltration of lymphocytes. Proliferation of kuffer cells, congestion of liver sinusoids and appearance of centrilobular necrotic patches. However treatment with ethanolic extract of flower of *Tagetes erecta* has shown dose dependant improvement in the liver architecture as indicated by the histopathological indication that there was reduction in the kuffer cells proliferation, reduced areas of lymphocytic infiltration and normalization of sinusoids. The biochemical and histopathological observation reveal that the 70% ethanolic extract of *Tagetes erecta* possess hepatoprotective activity in CCl₄ induced hepatotoxicity.

CCl₄ is metabolized to trichloromethyl CCl₃ radicals who are further converted to trichloromethyl peroxyl radical by superoxide anions. This CCl₃ is the main culprit in causing hepatotoxicity. This particular radical forms a covalent bond with sulphhydryl group of membrane GSH, protein thiols and unsaturated fats or lipids. This covalent bonding of free radicals with cellular macro molecules initiates the cascade

of reactions leading to lipid peroxidation^{1,17}. It was observed that the test extract shown significant reducing power and superoxide anion scavenging activity. Therefore pretreatment with flowers of *Tagetes erecta* extract may be preventing the formation of CCl₄ radical due to superoxide anion scavenging activity; Thereby tissue GSH levels are not depleted and lipid peroxidation is minimized, this may be the possible mechanism of hepatoprotection offered by ethanolic extract of flowers of *Tagetes erecta*.

CONCLUSION

In the present study, the hepatoprotective may be attributed to the antioxidant principles of the plant, namely rutin¹¹ and catechin¹⁸ and related flavonoids, tannins and other polyphenolic compounds. Further study is warranted to isolate, characterize and screen the active principles from the flower of *Tagetes erecta* that possess antioxidant and hepatoprotective property.

REFERENCES

1. Saleem TSM, Chetty CM, Ramkanth S, Rajan VST, Kumar KM, Gauthaman K. Hepatoprotective herbs—a review. *Int J Res Pharm Sci* 2010;1(1):1-5.
2. Adewusi EA, Afolayan AJ. A review of natural products with hepatoprotective activity. *J Med Plants Res* 2010;4(13):1318-34.
3. Sonkar N, Ganeshpurkar A, Yadav P, Dubey S, Bansal D, Dubey N. An experimental evaluation of nephroprotective potential of *Butea monosperma* extract in albino rats. *Indian J Pharmacol* 2014;46(1):109-12.
4. Hamburger M, Adler S, Baumann D, Förg A, Weinreich B. Preparative purification of the major anti-inflammatory triterpenoid esters from Marigold (*Calendula officinalis*). *Fitoterapia* 2003;74(4):328-38.
5. Bashir S, Gilani AH. Studies on the antioxidant and analgesic activities of Aztec marigold (*Tagetes erecta*) flowers. *Phyther Res An Int J Devoted to Pharmacol Toxicol Eval Nat Prod Deriv* 2008;22(12):1692-4.
6. Pérez Gutiérrez R, Hernández Luna H, Hernández Garrido S. Antioxidant activity of *Tagetes erecta* essential oil. *J Chil Chem Soc* 2006;51(2):883-6.
7. XU L, Juan C, QI H, SHI Y. Phytochemicals and their biological activities of plants in *Tagetes L.* *Chinese Herb Med* 2012;4(2):103-17.
8. Panche AN, Diwan AD, Chandra SR. Flavonoids: an overview. *J Nutr Sci* 2016;5.
9. Heim KE, Tagliaferro AR, Bobilya DJ. Flavonoid antioxidants: chemistry, metabolism and structure-activity relationships. *J Nutr Biochem* 2002;13(10):572-84.
10. Dubey PK, Ganeshpurkar A, Dubey S, Kakkar A. Isolation and studies on chemotherapeutic potential of aloin. *Int J Green Pharm* 2015;9(1):45-9.
11. Ganeshpurkar A, Saluja AK. The Pharmacological Potential of Rutin. *Saudi Pharm. J.* 2017;25(2):149-64.
12. Harborne JB. *Phytochemical Methods A Guide To Modern Techniques Of Plant Analysis*, Third Edition. Chapman Hall 1998;58.
13. Bruce RD. An up-and-down procedure for acute toxicity testing. *Fundam Appl Toxicol* 1985;5(1):151-7.
14. Lin H-M, Tseng H-C, Wang C-J, Lin J-J, Lo C-W, Chou F-P. Hepatoprotective effects of *Solanum nigrum* Linn extract against CCl₄-induced oxidative damage in rats. *Chem Biol Interact* 2008;171(3):283-93.
15. Chatterjee MN, Shinde R. *Medical biochemistry*. 2012.
16. Ahmad ST, Arjumand W, Nafees S, Seth A, Ali N, Rashid S, et al. Hesperidin alleviates acetaminophen induced toxicity in wistar rats by abrogation of oxidative stress, apoptosis and inflammation. *Toxicol Lett* 2012;208(2):149-61.
17. Cragg G. Natural products in drug discovery and development. *J Nat Prod* 1997;60(1):52-60.
18. Ganeshpurkar A, Saluja AK. Protective effect of catechin on humoral and cell mediated immunity in rat model. *Int Immunopharmacol* 2018;54:261-6.